



# AORTIC ARCH DEBRANCHING: ADVANCED AND HYBRID TECHNIQUES

Basel Ramlawi, M.D., M.M.Sc.; Michael J. Reardon, M.D.

Methodist DeBakey Heart & Vascular Center, The Methodist Hospital, Houston, Texas

B. Ramlawi, M.D., M.M.Sc.

## Abstract

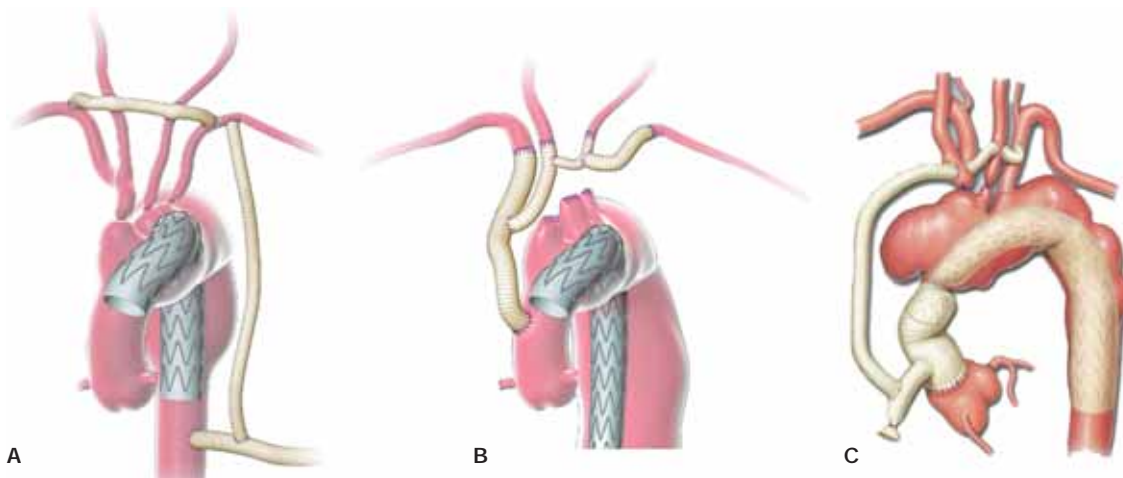
Aortic arch procedures have traditionally involved complex surgery with increased risk of mortality and morbidity. Throughout the last decade, however, novel and safe surgical approaches aimed at debranching the great vessels with definitive aortic arch repair have been developed. Currently, hybrid arch procedures allow for open or minimally invasive aortic access to be complemented by endovascular stent-graft techniques, which may eliminate the need for prolonged hypothermic circulatory arrest and its associated complications. Hybrid thoracic aortic and arch repairs have become the preferred approach, with open procedures performed only if hybrid approaches are not possible for technical reasons. In the future, aortic pathology may also benefit from the development of branched and fenestrated endografts that would be deployed in a modular fashion. This article describes the rationale, procedural steps, and recent outcomes data of novel aortic arch procedures.

## Introduction

Surgical management of patients with aortic pathology involving the arch and its branch vessels are traditionally challenging cases<sup>1</sup> leading to significant morbidity and mortality.<sup>2,3</sup> Recently, our group at the Methodist DeBakey Heart & Vascular Center (MDHVC), among others, has developed novel surgical approaches aimed at debranching the great vessels with definitive aortic arch repair as the goal. These recent hybrid advances in aortic arch repair are proving to be a safer and viable alternative to conventional open repair. Reducing morbidity of open arch reconstruction and expanding the indications of this life-saving therapy to higher-risk patients have been the goal.

There is now extensive data, as seen in the published consensus guidelines,<sup>4</sup> that aortic aneurysms should be followed closely and repair contemplated when aortic size exceeds 4.5 cm in diameter, or even smaller in certain patient groups with connective tissue

disorders or bicuspid aortic valves. The earliest repairs of thoracic aortic arch aneurysm (TAA) required extra-anatomic bypass to maintain cerebral blood flow, cardiopulmonary bypass (CPB) with resection and reconstruction of the thoracic aorta, and subsequent take down of the previously created extra-anatomic bypass. Griep simplified the procedure by introducing profound hypothermia and circulatory arrest to allow cerebral protection during aortic arch resection.<sup>5</sup> Results from the Mayo group in a series of 95 open aortic arch repairs showed a mortality of 16.8% and a stroke rate of 9.5%.<sup>6</sup> The introduction of axillary cannulation and antegrade cerebral perfusion decreased both mortality and stroke rate to 6%, still highlighting the complexity of this disease. For our increasingly elderly and frail patients, open aortic arch repair is associated with an in-hospital mortality of up to 20% and a stroke rate of up to 12%.<sup>7,8</sup> For patients with significant comorbidities, open surgical repair may not be a viable option due to prohibitive estimated



**Figure 1.** (A) Arch vessels debranching using 14-mm inflow conduit from ascending aorta followed by 10-mm bypass graft to the innominate, left common carotid, and left subclavian arteries. (B) Arch vessels debranching using 10-mm Dacron graft with retrograde inflow through 10-mm graft. Endograft was delivered using 14-mm conduit. (C) Arch vessels showing a 10-mm limb being sutured to a 14-mm trunk. The 10-mm limb is tunneled superiorly to revascularize the supra-aortic trunks, whereas the 14-mm trunk is used as the conduit for antegrade stent-graft placement. The 14-mm stump is oversewn after completion of the stent-graft deployment.<sup>10-11</sup>

Figures A and B reprinted with permission from Elsevier/Society for Vascular Surgery/Department of Cardiovascular Surgery, Methodist DeBakey Heart & Vascular Center. Figure C reprinted with permission from Elsevier/Society for Vascular Surgery.

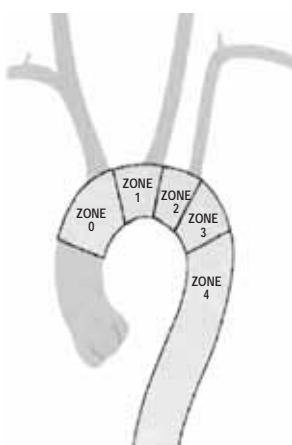
mortality and permanent morbidity. Hybrid repair of TAA has been developed to address these high-risk patients without using circulatory arrest and CPB, which can be poorly tolerated.<sup>9-12</sup>

### Rationale for Hybrid Approach

The traditional open repair of TAA is heavily influenced by the need for CPB, cardiac arrest, and profound hypothermia with circulatory arrest.<sup>13-18</sup> Thoracic aneurysms that require coverage of the innominate artery or the left subclavian artery for proper graft fixation are not amenable to standard, isolated endovascular techniques.<sup>19-21</sup> TAA can be isolated or involve the ascending and/or descending thoracic aorta, in which case they can be repaired by extra-anatomic bypass of the cerebral vessels and left subclavian when desired, along with antegrade or retrograde endograft deployment with CPB, cardiac arrest, or circulatory arrest, thereby removing many technical risk factors.<sup>22-29</sup> For TAA involving the ascending thoracic aorta, CPB and cardiac arrest are necessary for ascending aortic replacement, but debranching and endograft repair will eliminate the need for profound hypothermia and circulatory arrest (Figure 1).

### Technical Issues With Arch Aneurysms

Endograft repair of aneurysms requires anatomically appropriate landing zones for the proper fixation and sealing of the aneurysm at its proximal and distal extent. It also requires that critically important arteries not be covered unless these are revascularized using some method, and it requires access to deliver the graft for deployment. The thoracic aorta has been divided into five zones. Zone 0 includes the ascending aorta to just beyond the origin of the innominate artery. Zone 1 extends from the end of zone 0 to just beyond the origin of the left carotid artery. Zone 2 begins at the end of zone 1 and extends to the origin of the left subclavian artery. Zone 3 represents the proximal descending thoracic aorta from the left subclavian to the mid-descending thoracic aorta. Zone 4 comprises the rest of the descending thoracic aorta (Figure 2). Endograft coverage of zones 0 or 1 will cover vital cerebral blood flow from the innominate and/or left carotid arteries and cannot be done without establishing an extra-anatomic route of blood flow. Endografts that cover zone 2 will cover the left subclavian artery. Although it can be covered without an untoward effect in some patients, there is a belief that revascularization of the left subclavian in these circumstances may improve outcomes.<sup>30</sup> Even when appropriately revascularized,



**Figure 2.** Ishimaru arch map according to the different landing zones.<sup>42</sup> Reprinted with permission from Elsevier/The American Association for Thoracic Surgery.

landing an endograft in the aortic arch may pose a technical challenge due to the curvature of the arch and potential “bird beaking” of the graft.<sup>31</sup> Each of the techniques used to allow endograft coverage of the aortic arch are extending the proximal “branchless” section of the descending thoracic aorta to allow an appropriate proximal landing zone. The final technical consideration is the feasibility of delivering the stent graft to the site of deployment in an antegrade or a retrograde fashion.

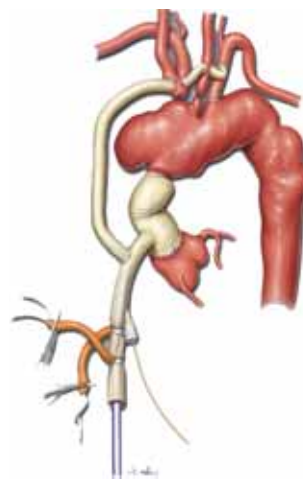
### Hybrid Aortic Arch Techniques

The technique used for aortic arch repair is largely dependent on the patient’s anatomy and the nature of the pathology (dissection vs.

aneurysm).<sup>32-35</sup> Aneurysms involving the ascending aorta usually mandate use of CPB and hypothermic circulatory arrest during the open distal anastomosis. However, using the novel hybrid and debranching approaches described below, the time required and morbidity are diminished significantly. Arch aneurysms not involving the ascending aorta can typically be repaired using an arch debranching procedure without CPB, with endovascular repair across the arch and proximal descending thoracic aorta using a landing zone within the normal ascending aorta. The following describes the surgical approach adopted at MDHVC based on the affected anatomy.

### Ascending Aortic Involvement

If the ascending aorta is involved and must be replaced, we use a standard median sternotomy for surgical access. CPB, cardioplegic cardiac arrest, and standard distal ascending aortic cross clamp technique are used for ascending aortic replacement. The arch aneurysm is left in place, thus avoiding profound hypothermia and circulatory arrest. A 12-mm graft is attached to the proximal ascending graft, and its separate side arms are constructed and attached end-to-end to the innominate, left carotid, and left subclavian arteries. This allows the proximal stent graft to land in the distal ascending graft to provide a safe seal (Figure 3).

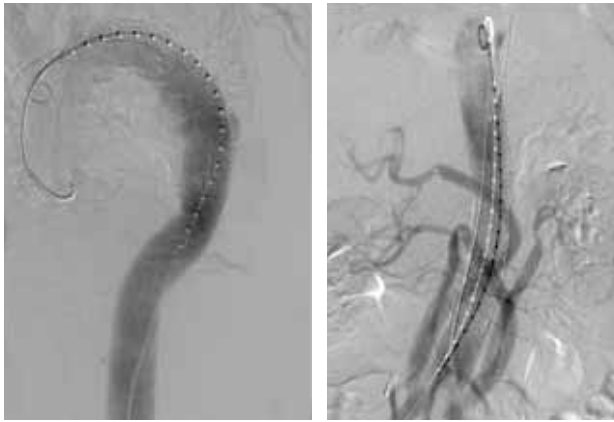

**Figure 3.** Extra-anatomic debranching of aortic arch vessels with replacement of ascending aorta and antegrade TEVAR via Dacron side branch.<sup>12</sup> Reprinted with permission from Elsevier/Society for Vascular Surgery.

### Ascending Aorta Not Involved but Innominate Artery Involved

When the ascending aorta does not need to be replaced, the entire procedure can be done without stopping the heart. Surgical access may be via a standard median sternotomy or mini-right anterior thoracotomy and cervical incisions. Median sternotomy allows attachment of a 12-mm graft to the proximal ascending aorta using a side-biting clamp. Care must be taken to lower the systemic blood pressure to avoid dissection or premature clamp release and to attach this graft far enough proximally to allow an adequate landing zone in the ascending aorta. Because this graft is used for antegrade stent graft deployment, we bolster the anastomosis with a pledgeted

suture at the toe and heel of the ascending aortic attachment to prevent disruption. Side arm grafts are individually constructed and attached to the innominate, left carotid, and left subclavian arteries. After this step, it is easier to attach the left subclavian graft previously sewn to the left subclavian in an end-to-side manner to the existing left carotid graft. Once the arch has been completely reconstructed in this extra-anatomic fashion, the stent graft is deployed in an antegrade manner through the 12-mm graft attached to the ascending aorta. The distal extent of the stent graft depends on the distal extent of the aneurysm and achieving an adequate distal landing zone. This approach for debranching the entire aortic arch



**Figure 4.** Completion angiography after stent grafting in a patient who underwent arch and abdominal debranching shows the patency of bypass grafts and the exclusion on the aneurysm.<sup>10</sup> Reprinted with permission from Elsevier/Society for Vascular Surgery.

and celiac and superior mesenteric arteries allows a distal graft landing just above the renal arteries (Figure 4).

### ***Innominate Not Involved***

If the endograft has a proximal landing zone that must cover the left carotid and left subclavian arteries, cervical incisions only for right carotid to left carotid bypass and a left carotid subclavian bypass can be carried out with retrograde endograft deployment.

### ***Minimally Invasive Arch Repair***

The alternative to a median sternotomy is a small anterior right thoracotomy, as described for minimally invasive access for aortic valve replacement and cervical incisions. Recently, we reported a minimally invasive, non-sternotomy approach to debranching the aortic arch that may prove to be useful in frail and debilitated patients for whom reducing surgical trauma would be of significant benefit.<sup>36</sup> For this approach, a small incision at the lower sternocleidomastoid muscle on each side allows access to the right and left common carotid arteries. A small left supraclavicular incision exposes the left subclavian artery. A 10-mm Dacron graft

is pre-sewn onto a 12-mm graft on the back table and tailored to fit the proximal ascending aorta; the 12-mm graft is then attached to the proximal ascending aorta. At the completion of this anastomosis, clamps are placed on the 12-mm and the 10-mm grafts, and the side-biting clamp is removed. Pledged sutures are again placed at the toe and heel of the ascending attachment, and the anastomosis is carefully inspected for any bleeding.

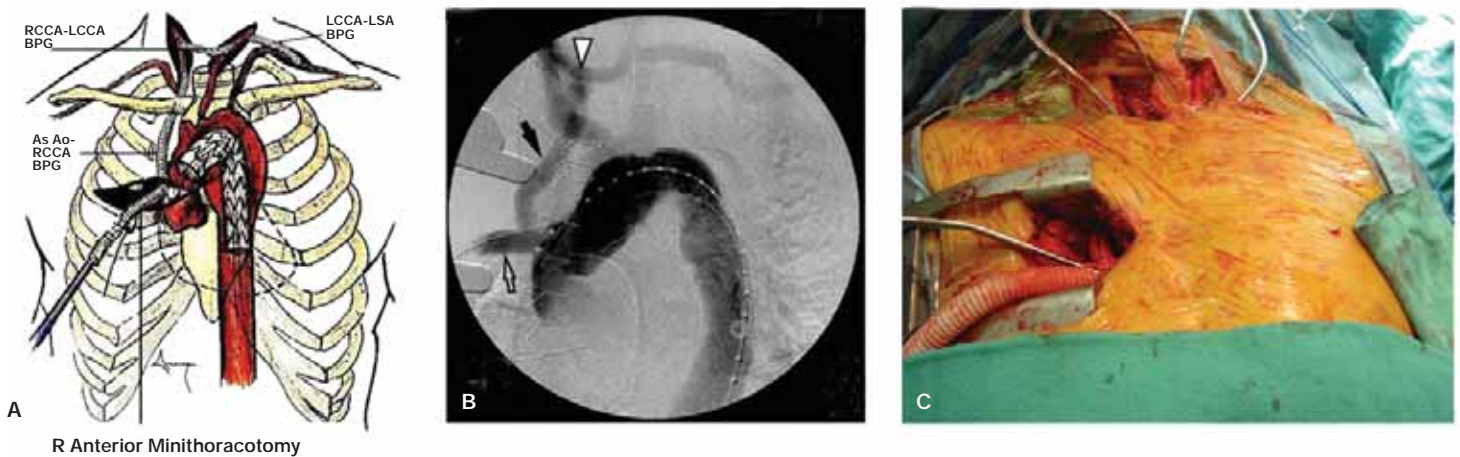
At this point the 10-mm graft is within the chest, next to the ascending aorta, and would not be an easy anastomosis to perform if not already done. The 10-mm graft must then be passed through the sternal outlet into the right cervical incision for anastomosis to the right common carotid artery; exit the sternum in the midline and against the posterior table of the sternum to avoid injury to the innominate vein. An 8-mm graft is then attached to this 10-mm graft and passed anterior to the trachea, making a loop low behind the upper sternum; it is then attached to the left common carotid artery leaving the trachea uncovered by graft. A standard left carotid subclavian bypass completes the arch debranching. The proximal left carotid and innominate arteries are ligated to prevent type II endoleaks. The left subclavian is closed proximally with a coil or plug via the left arm to prevent endoleak while preserving the vertebral artery. Antegrade deployment of the stent graft can then be carried out via the original 12-mm graft attached to the ascending aorta.

We treat most aortic arch hybrid cases as a single stage using antegrade deployment, whereas visceral debranching and stent grafting for thoracoabdominal aortic aneurysm are performed as a staged procedure with retrograde deployment (Figure 5).<sup>37</sup>

### **Results**

Hybrid arch procedures provide a safe and viable alternative to traditional open surgical repair. In general, hybrid approaches have a lower mortality and morbidity for high-risk older patients. Recently, such approaches have extended hybrid repair indications for complex arch pathology once thought to be prohibitively high risk for open arch surgical repair.

At our institution, hybrid thoracic aortic and arch repairs have become the preferred approach, with open procedures performed only if hybrid approaches are not possible for technical reasons.



**Figure 5.** (A) Schematic drawing showing the procedure. Via a 5-cm incision at the third intercostal space to access the ascending arch, a 12-mm–10-mm bifurcated hemashield Dacron graft is created. A partial occluding clamp is used on the ascending aorta to attach the 10-mm arm of the bifurcated 10/12-mm graft to the right common carotid or innominate artery. Remaining arch vessels are bypassed through carotid-carotid and left carotid-subclavian bypass. Antegrade stenting of the aortic arch is carried out through the RAM via the remaining 12-mm limb.<sup>36</sup> (B) Intraoperative angiogram showed the ascending aorta to right common carotid artery (RCCA) bypass graft (black arrow), RCCA to LCCA bypass graft (white arrow), and the stent graft deployment via a 12-mm limb (hollow arrow) through the anterior minithoracotomy and complete exclusion of the aneurysmal sac.<sup>36</sup> (C) Intraoperative photograph.<sup>10</sup>

Figures A and B reprinted with permission from Elsevier/The American Association for Thoracic Surgery. Figure C reprinted with permission from Elsevier/Society for Vascular Surgery.

Complication	Hybrid Aneurysm (n=33)	Hybrid Dissection (n=7)	P value
MI	6%	0%	1
Respiratory Failure	33%	20%	0.65
Renal failure	15%	20%	1
GI	24%	0%	0.38
SCI	15%	0%	0.56
CVA/TIA	18%	40%	0.61
Death (30 days)	24%	0%	0.31
Composite endpoint	13%	0%	0.07

**Table 1.** Comparison of the outcome of aneurysm and dissection (%).<sup>10</sup> CVA: cerebrovascular accident; GI: gastrointestinal; MI: myocardial infarction; SCI: spinal cord ischemia; TIA: transient ischemic attack. Composite endpoint is the combined death and permanent paraplegia rate at 30 days.

Reprinted with permission from Elsevier/Society for Vascular Surgery.

In our experience with hybrid aortic repair in patients who were denied open surgery due to preoperative comorbidities and low physiologic reserve, 55% were symptomatic on presentation and 83% were done emergently; 76% underwent debranching of the aortic arch, 17% of the visceral vessels, and 7% required both. Primary technical success was achieved in all cases, and of these, 43% were staged. The 30-day mortality was 5%. Myocardial infarction developed in 6% and respiratory failure in 33% (Table 1). These hybrid approaches, while initially performed mostly for very sick or emergent cases, proved the technical feasibility of the procedure given the medical and anatomical complexity of these patients, with encouraging results.<sup>9-12</sup>

Milewski and coworkers compared a hybrid arch repair cohort with an open aortic arch repair cohort and found a trend for lower incidence of neurologic deficit of 4% compared to 9% per group, while the short-term/in-hospital mortality rate was 11% and 16%, respectively. The only statistically significant difference was the mortality rate between age groups and not among surgical approaches: the older patients (over 75 years old) had a higher mortality rate of 36%.<sup>38</sup>

In another series reported by Hughes and colleagues, 28 patients underwent hybrid arch repair with 30-day in-hospital rates of death, stroke, and permanent paraplegia/paresis of 0%, 0%, and 3.6%, respectively.<sup>39</sup> At a mean follow-up of 14 ± 11 months, there were no late aortic-related events. Two patients (7%) required secondary endovascular reintervention for a type 1 endovascular leak. No patient has shown a type 1 or 3 endovascular leak at latest follow-up.<sup>39-41</sup> Similarly, Canaud reported a 6.8% risk of stroke with an actuarial survival of 70% at a mean follow-up of 29.9 months.<sup>42</sup>

Regardless of the configuration used, hybrid approaches to arch repair are achieving similar or better short- and long-term outcomes compared to the open arch replacement procedures in most reported series.

## Conclusion

Regardless of the approach selected, aortic arch pathology remains a challenging surgical undertaking. Open aortic arch repair for aortic arch aneurysm can be carried out at reasonable but not insignificant risk in appropriate patients. The hybrid endovascular stent graft approach has been developed in an attempt to decrease the mortality and morbidity of open arch repair and to allow extension of life-saving therapy to high-risk patients who may not be reasonable candidates for open repair.

In the future, aortic pathology may also benefit from the

development of branched and fenestrated endografts that would be deployed in a modular fashion.<sup>43</sup> This technology would allow us to potentially debranch the aortic arch from the inside, further minimizing the surgical insult.

Please direct all correspondence to Basel Ramlawi, M.D., M.M.Sc., 6550 Fannin St., Suite 1401, Houston, TX 77030, 713-441-5200, BRamlawi@tmhs.org.

## References

- DeBakey ME, McCollum CH, Graham JM. Surgical treatment of aneurysms of the descending thoracic aorta: long-term results in 500 patients. *J Cardiovasc Surg (Torino)*. 1978 Nov-Dec;19(6):571-6.
- Clouse WD, Hallett JW Jr, Schaff HV, Gayari MM, Ilstrup DM, Melton LJ 3rd. Improved prognosis of thoracic aortic aneurysms: a population-based study. *JAMA*. 1998 Dec 9; 280(22):1926-9.
- Juvonen T, Ergin MA, Galla JD, Lansman SL, Nguyen KH, McCullough JN, et al. Prospective study of the natural history of thoracic aortic aneurysms. *Ann Thorac Surg*. 1997 Jun;63(6):1533-45.
- Hiratzka LF, Bakris GL, Beckman JA, Bersin RM, Carr VF, Casey DE Jr, et al. 2010 ACCF/AHA/AATS/ACR/ASA/SCA/SCAI/SIR/STS/SVM guidelines for the diagnosis and management of patients with Thoracic Aortic Disease: a report of the American College of Cardiology Foundation/American Heart Association Task Force on Practice Guidelines, American Association for Thoracic Surgery, American College of Radiology, American Stroke Association, Society of Cardiovascular Anesthesiologists, Society for Cardiovascular Angiography and Interventions, Society of Interventional Radiology, Society of Thoracic Surgeons, and Society for Vascular Medicine. *Circulation*. 2010 Apr 6;121(13):e266-369.
- Griep RB, Stinson EB, Oyer PE, Copeland JG, Shumway NE. The superiority of aortic cross-clamping with profound local hypothermia for myocardial protection during aorta-coronary bypass grafting. *J Thorac Cardiovasc Surg*. 1975 Dec;70(6):995-1009.
- Sundt TM 3rd, Orszulak TA, Cook DJ, Schaff HV. Improving results of open arch replacement. *Ann Thorac Surg*. 2008 Sep;86(3):787-96.
- Coselli JS, Buket S, Djukanovic B. Aortic arch operation: current treatment and results. *Ann Thorac Surg*. 1995 Jan;59(1):19-26; discussion 26-7.
- Svensson LG, Crawford ES, Hess KR, Coselli JS, Raskin S, Shenaq SA, et al. Deep hypothermia with circulatory arrest. Determinants of stroke and early mortality in 656 patients. *J Thorac Cardiovasc Surg*. 1993 Jul;106(1):19-28.
- Mussa FF, Walkes JC, Lumsden AB, Reardon MJ. Novel technique for arch and visceral artery debranching using ascending aortic inflow. *Vascular*. 2008 Sep-Oct;16(5):275-8.
- Younes HK, Davies MG, Bismuth J, Naoum JJ, Peden EK, Reardon MJ, et al. Hybrid thoracic endovascular aortic repair: pushing the envelope. *J Vasc Surg*. 2010 Jan;51(1):259-66.
- Zhou W, Reardon M, Peden EK, Lin PH, Lumsden AB. Hybrid approach to complex thoracic aortic aneurysms in high-risk patients: surgical challenges and clinical outcomes. *J Vasc Surg*. 2006 Oct;44(4):688-93.
- Zhou W, Reardon ME, Peden EK, Lin PH, Bush RL, Lumsden AB. Endovascular repair of a proximal aortic arch aneurysm: a novel approach of supra-aortic debranching with antegrade endograft deployment via an anterior thoracotomy approach. *J Vasc Surg*. 2006 May;43(5):1045-8.

13. Di Eusanio M, Schepens MA, Morshuis WJ, Dossche KM, Di Bartolomeo R, Pacini D, et al. Brain protection using antegrade selective cerebral perfusion: a multicenter study. *Ann Thorac Surg.* 2003 Oct;76(4):1181-8.
14. Kazui T, Washiyama N, Muhammad BA, Terada H, Yamashita K, Takinami M. Improved results of atherosclerotic arch aneurysm operations with a refined technique. *J Thorac Cardiovasc Surg.* 2001 Mar;121(3):491-9.
15. Keeling WB, Kerendi F, Chen EP. Total aortic arch replacement for the treatment of Kommerell's diverticulum in a Jehovah's Witness. *J Card Surg.* 2010 May;25(3):333-5.
16. Ogino H, Ueda Y, Sugita T, Matsuyama K, Matsubayashi K, Nomoto T, et al. Aortic arch repairs through three different approaches. *Eur J Cardiothorac Surg.* 2001 Jan;19(1):25-9.
17. Spielvogel D, Halstead JC, Meier M, Kadir I, Lansman SL, Shahani R, et al. Aortic arch replacement using a trifurcated graft: simple, versatile, and safe. *Ann Thorac Surg.* 2005 Jul;80(1):90-5.
18. Ueda Y. Retrograde cerebral perfusion with hypothermic circulatory arrest in aortic arch surgery: operative and long-term results. *Nagoya J Med Sci.* 2001 Nov;64(3-4):93-102.
19. Bavaria JE, Appoo JJ, Makaroun MS, Verter J, Yu ZF, Mitchell RS. Endovascular stent grafting versus open surgical repair of descending thoracic aortic aneurysms in low-risk patients: a multicenter comparative trial. *J Thorac Cardiovasc Surg.* 2007 Feb;133(2):369-77.
20. Greenhalgh RM, Brown LC, Powell JT, Thompson SG, Epstein D, Sculpher MJ. Endovascular versus open repair of abdominal aortic aneurysm. *N Engl J Med.* 2010 May 20;362(20):1863-71.
21. Makaroun MS, Dillavou ED, Wheatley GH, Cambria RP. Five-year results of endovascular treatment with the Gore TAG device compared with open repair of thoracic aortic aneurysms. *J Vasc Surg.* 2008 May;47(5):912-8.
22. Akhyari P, Kamiya H, Heye T, Lichtenberg A, Karck M. Aortic dissection type A after supra-aortic debranching and implantation of an endovascular stent-graft for type B dissection: A word of caution. *J Thorac Cardiovasc Surg.* 2009 May;137(5):1290-2.
23. Chiesa R, Tshomba Y, Melissano G, Marone EM, Bertoglio L, Setacci F, et al. Hybrid approach to thoracoabdominal aortic aneurysms in patients with prior aortic surgery. *J Vasc Surg.* 2007 Jun;45(6):1128-35.
24. Donas KP, Lachat M, Rancic Z, Oberkofler C, Pfammatter T, Guber I, et al. Early and midterm outcome of a novel technique to simplify the hybrid procedures in the treatment of thoracoabdominal and pararenal aortic aneurysms. *J Vasc Surg.* 2009 Dec;50(6):1280-4.
25. Esposito G, Marullo AG, Pennetta AR, Bichi S, Conte M, Cricco AM, et al. Hybrid treatment of thoracoabdominal aortic aneurysms with the use of a new prosthesis. *Ann Thorac Surg.* 2008 Apr;85(4):1443-5.
26. Greenberg RK, Haddad F, Svensson L, O'Neill S, Walker E, Lyden SP, et al. Hybrid approaches to thoracic aortic aneurysms: the role of endovascular elephant trunk completion. *Circulation.* 2005 Oct 25;112(17):2619-26.
27. Kawaharada N, Kurimoto Y, Ito T, Koyanagi T, Yamauchi A, Nakamura M, et al. Hybrid treatment for aortic arch and proximal descending thoracic aneurysm: experience with stent grafting for second-stage elephant trunk repair. *Eur J Cardiothorac Surg.* 2009 Dec;36(6):956-61.
28. Rancic Z, Pfammatter T, Lachat M, Frauenfelder T, Veith FJ, Mayer D. Floating aortic arch thrombus involving the supraaortic trunks: successful treatment with supra-aortic debranching and antegrade endograft implantation. *J Vasc Surg.* 2009 Nov;50(5):1177-80.
29. Szeto WY, Bavaria JE, Bowen FW, Woo EY, Fairman RM, Pochettino A. The hybrid total arch repair: brachiocephalic bypass and concomitant endovascular aortic arch stent graft placement. *J Card Surg.* 2007 Mar-Apr;22(2):97-102.
30. Holt PJ, Johnson C, Hinchliffe RJ, Morgan R, Jahingiri M, Loftus IM, et al. Outcomes of the endovascular management of aortic arch aneurysms: implications for management of the left subclavian artery. *J Vasc Surg.* Jun;51(6):1329-38.
31. Wang S, Chang G, Li X, Hu Z, Li S, Yang J, et al. Endovascular treatment of arch and proximal thoracic aortic lesions. *J Vasc Surg.* 2008 Jul;48(1):64-8.
32. Donas KP, Czerny M, Guber I, Teufelsbauer H, Nanobachvili J. Hybrid open-endovascular repair for thoracoabdominal aortic aneurysms: current status and level of evidence. *Eur J Vasc Endovasc Surg.* 2007 Nov;34(5):528-33.
33. Saleh HM, Inglese L. Combined surgical and endovascular treatment of aortic arch aneurysms. *J Vasc Surg.* 2006 Sep;44(3):460-6.
34. Shimamura K, Kuratani T, Matsumiya G, Kato M, Shirakawa Y, Takano H, et al. Long-term results of the open stent-grafting technique for extended aortic arch disease. *J Thorac Cardiovasc Surg.* 2008 Jun;135(6):1261-9.
35. Zierer A, Sanchez LA, Moon MR. Combined open proximal and stent-graft distal repair for distal arch aneurysms: an alternative to total debranching. *Ann Thorac Surg.* 2009 Jul;88(1):307-9.
36. Anaya-Ayala JE, Cheema ZF, Davies MG, Bismuth J, Ramlawi B, Lumsden AB, et al. Hybrid thoracic endovascular aortic repair via right anterior minithoracotomy. *J Thorac Cardiovasc Surg.* 2011 Aug;142(2):314-8.
37. Estrera AL, Miller CC 3rd, Porat EE, Huynh TT, Winnerkvist A, Safi HJ. Staged repair of extensive aortic aneurysms. *Ann Thorac Surg.* 2002 Nov;74(5):S1803-5.
38. Milewski RK, Szeto WY, Pochettino A, Moser GW, Moeller P, Bavaria JE. Have hybrid procedures replaced open aortic arch reconstruction in high-risk patients? A comparative study of elective open arch debranching with endovascular stent graft placement and conventional elective open total and distal aortic arch reconstruction. *J Thorac Cardiovasc Surg.* 2010 Sep;140(3):590-7.
39. Hughes GC, Daneshmand MA, Balsara KR, Achneck HA, Sileshi B, Lee SM, et al. "Hybrid" repair of aneurysms of the transverse aortic arch: midterm results. *Ann Thorac Surg.* 2009 Dec;88(6):1882-7.
40. Hughes GC, McCann RL. Hybrid thoracoabdominal aortic aneurysm repair: concomitant visceral revascularization and endovascular aneurysm exclusion. *Semin Thorac Cardiovasc Surg.* 2009 Winter;21(4):355-62.
41. Hughes GC, Nienaber JJ, Bush EL, Daneshmand MA, McCann RL. Use of custom Dacron branch grafts for "hybrid" aortic debranching during endovascular repair of thoracic and thoracoabdominal aortic aneurysms. *J Thorac Cardiovasc Surg.* 2008 Jul;136(1):21-8, 28.e1-6.
42. Canaud L, Hireche K, Berthet JP, Branchereau P, Marty-Ane C, Alric P. Endovascular repair of aortic arch lesions in high-risk patients or after previous aortic surgery: midterm results. *J Thorac Cardiovasc Surg.* 2010 Jul;140(1):52-8.
43. Chuter JA, Hiramoto JS, Chang C, Wakil L, Schneider DB, Rapp JH, et al. Branched stent-grafts: will these become the new standard? *J Vasc Interv Radiol.* 2008 Jun;19(6 Suppl):S57-62.