



FENESTRATED AND BRANCHED ENDOGRAFTS

Mark G. Davies, M.D., Ph.D., M.B.A.; Javier E. Anaya-Ayala, M.D.; Alan B. Lumsden, M.D.
Methodist DeBakey Heart & Vascular Center, The Methodist Hospital, Houston, Texas

M.G. Davies, M.D., Ph.D., M.B.A.

Abstract

Thoracoabdominal aneurysm repair is undergoing a paradigm shift. The evolution of branched and fenestrated grafts has expanded the use of endografts to the visceral aorta and the arch of the aorta and broadened the spectrum of patients who can now be considered suitable for endografting.

In turn, these advances have led to a decrease in mortality and morbidity at specialized centers and are propelling the development of a series of modular devices to facilitate wider dispersion of the technology. Preoperative case planning, advanced imaging, and technical experience are keys to successful outcomes. This review examines the current state of fenestrated and branched endografting and the workarounds that have been developed to increase the use of endovascular aortic repair (EVAR).

Current Clinical Issue

Open thoracoabdominal aortic repair is a significant physiological challenge to any patient and is associated with a sobering pattern of outcomes when examining the global experience. However, many individual high-volume centers do report good outcomes, with mortality and morbidity rates dependent on the health of the patient, the extent of the aneurysm, the skill of the surgeon, and the quality of perioperative care.¹ Treatment of many infrarenal and descending thoracic pathologies has shifted to endovascular grafting.²⁻⁵ Endovascular repair of the descending thoracic aorta has demonstrated a marked reduction in the physiological challenge, a reduction in morbidity, and improved long-term outcomes.⁶ Currently, the use of endovascular techniques within the aorta is limited by the need for sufficient proximal and distal landing zones and the need to maintain satisfactory flow to the major branches of the arch, the visceral segment, and the internal iliacs. Two endovascular systems have been developed and trialed to overcome these limitations: fenestrated stent-grafts and branched stent-grafts. Fenestrated grafts have holes in the fabric that are positioned adjacent to the aortic branch artery orifices. These fenestrations are secured to the aortic branch artery ostia by deploying smaller, covered stents (side branches) through the branched fenestrations and into the target arterial branches. Grafts may also contain scallops to accommodate branches without compromising the seal zone. Branched grafts, on the other hand, incorporate pre-attached limbs or cuffs targeted for the aortic branches and are directed and deployed into the branch, thus avoiding a junction and the need for a second covered stent. Preoperative case planning, advanced imaging, and technical experience are critical to successful outcomes. Availability of these two designs is limited to specialty centers, and this has spurred the development of other off-label techniques, including parallel stenting (chimney or snorkel techniques), dual bifurcated stent deployments, and on-table modification of commercially available stent grafts.

Abdominal and visceral aorta

Chimneys, Snorkels and Periscopes

The principle of parallel stenting is to place a covered stent in a target aortic branch and extend the stent into the lumen of the aorta at the level of the landing zone, such that the small covered stent is within a gutter of the graft and allows perfusion of the target branch directly from the oncoming flow of blood. This can be used for the main renal arteries, the superior mesenteric artery (SMA), and the celiac artery where there is an insufficient proximal landing zone (Figure 1). The snorkel technique allows the small covered stent to be placed in the gutter of the graft, but in this case the inflow is from the bounce back from the iliac or femoral bifurcation and is indirect flow. This can be used for the visceral vessels, the renals,⁷ and the internal iliacs. The secret to a

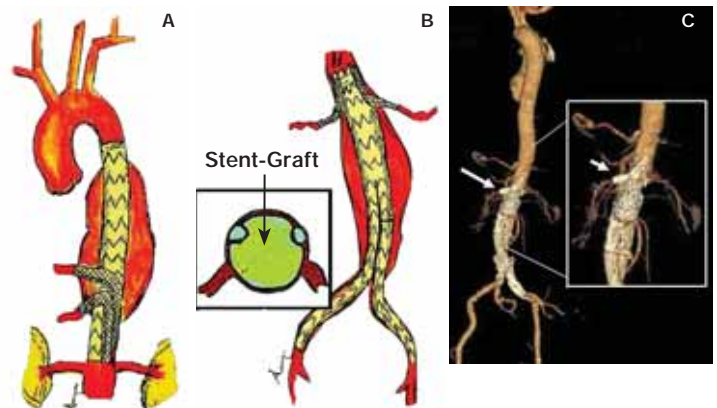


Figure 1. (A) The illustration demonstrates a double periscope technique to maintain patency in the celiac and SMA during thoracic endografting. (B) The illustration demonstrates a double chimney technique to maintain patency in both renals during juxtarenal endografting. (C) The computed tomography (CT) reconstruction shows a juxtarenal endograft with a single chimney graft to preserve the renal artery. The inset is a close-up of this area. Reprinted with permission from the Department of Cardiovascular Surgery, Methodist DeBakey Heart & Vascular Center.

Bifurcated Endograft to Maintain Flow to Both Internal Iliac Arteries

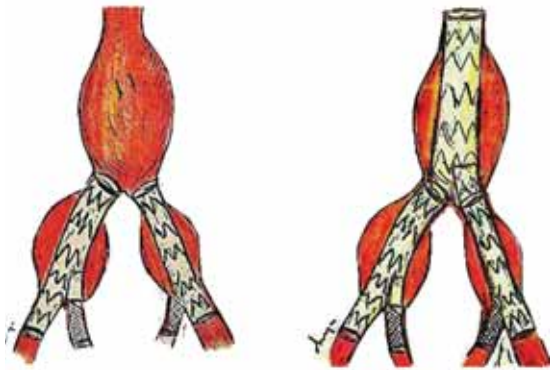


Figure 2. The illustration demonstrates a bilateral double endograft technique to maintain patency in the bilateral internal iliac arteries during abdominal aortic endografting. Reprinted with permission from the Department of Cardiovascular Surgery, Methodist DeBakey Heart & Vascular Center.

successful chimney or snorkel is to spiral the covered stent around the primary device and avoid a direct gutter inline with the blood flow, thus avoiding a type 1 endoleak. Case reports and small case series have suggested that this technique is effective in the short term.⁸

Dual Bifurcated Endograft Deployments

The principle of this technique is to deploy a second bifurcated device within the limb of a primary EVAR device to maintain flow to one or both internal iliac arteries (Figure 2). The limitation of this technique is the size requirement of the primary graft limb and the recipient vessel. It is also technically more difficult, and the risk-benefit ratio is unknown. Case reports suggest that this technique is technically achievable and effective in the short term.

Institutional Off-Label Modification of Commercial Endografts

The final technique is to modify an FDA-approved device on the back table with scallops or fenestrations such that there are one or more ostia or uncovered areas for the visceral and renal vessels

Fenestrated and Branched Endografts

Celiac and SMA Branches



Celiac, SMA and Renal Branches



Figure 3. The illustration demonstrates (right) a branched thoracic graft used to maintain flow to the celiac and SMA vessels, and (left) a fenestrated graft used to treat a type IV abdominal aortic aneurysm and maintain flow to the visceral and renal vessels. Reprinted with permission from the Department of Cardiovascular Surgery, Methodist DeBakey Heart & Vascular Center.

in the abdomen. This represents an off-label modification of the device and carries significant legal and regulatory ramifications. A second technique that has emerged is in situ (in vivo) fenestration using a laser, cutting wire, or needle. This approach has been applied in the arch of the aorta with some early success.

Commercial Fenestrated and Branched Endografts

Several commercial companies are developing first- and second-generation fenestrated and branched endografts in both modular and non-modular designs (Figure 3). In selected patients, fenestrated and branched stents appear to be a safe and effective alternative to open surgery for juxtarenal and thoracoabdominal aneurysms, with low complication and mortality rates. Sixty percent of thoracoabdominal aortic aneurysms (TAAAs) would be suitable for branched/fenestrated stent grafting, but 40% are unsuitable due to adverse anatomy.⁹

In a prospective analysis of 119 patients undergoing implantation of a fenestrated endovascular device with short proximal necks (3–10 mm), Greenberg et al. demonstrated 100% technical success without the acute loss of any visceral arteries.^{10, 11} The 30-day endoleak rate was 10% (all type II). In-stent stenoses occurred in 12 renal arteries and 1 SMA. The SMA and 6 renal arteries were treated, and 2 renal stenoses are awaiting treatment; 10 of 231 stented renal arteries occluded (3 prior to discharge). Similar results have been reported by other groups.^{12–15} The clinical outcomes of the U.S. multicenter study of 30 patients are concordant with previous single-center studies.¹⁶ The recent Association Universitaire de Recherche en Chirurgie Vasculaire study of 80 patients with fenestrated grafts in a total of 237 visceral vessels showed that 99% of the target vessels were patent at completion of the case.¹⁷ Predischarge imaging identified 9 (11%) endoleaks: 3 were type I, 5 were type II, and 1 was type III. No aneurysms ruptured or required open conversion during the follow-up period. One patient had sac enlargement within the first year, associated with a persistent type II endoleak. In-stent stenoses or occlusion affected 4 renal arteries, of which 3 underwent reintervention. A standardized, off-the-shelf, multi-branched stent-graft is applicable in 88% of cases of TAAA.¹⁸ Moderate degrees of cuff-to-artery misalignment had no effect on the efficacy of multi-branched stent-graft insertion.¹⁹

Preservation of pelvic circulation in high-risk patients treated for bilateral or unilateral common iliac aneurysms combined with or without abdominal aortic aneurysm is a small but significant clinical problem (Figure 4).²⁰ Nine series have reported the use of iliac branch devices (IBD) in a total of 196 patients.²¹ Technical success was 85–100% with no aneurysm-related mortality. Iliac artery occlusion occurred in 24 of 196 patients. When comparing the first- with the second-generation IBD outcomes, cumulative patency rates at 2 years revealed no statistical difference. No endoleak, and particularly no IBD, modular side branch disconnection, late

Bifurcated Endograft for the Internal Iliac Artery

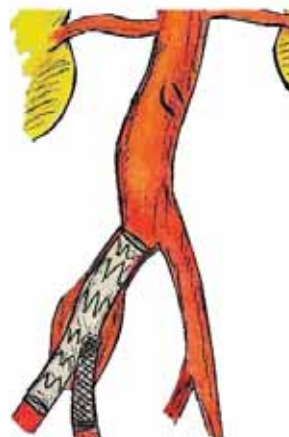

Figure 4. The illustration demonstrates an iliac branched endograft employed to maintain flow to the internal iliac artery during iliac aneurysm endografting. Reprinted with permission from the Department of Cardiovascular Surgery, Methodist DeBakey Heart & Vascular Center.

Aortic Arch Branch Devices

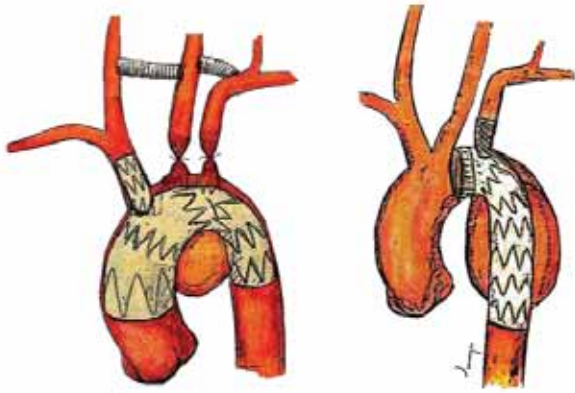


Figure 5. The illustration demonstrates a branched thoracic endograft with and without supra-aortic vessel bypass to treat an arch aneurysm.

Reprinted with permission from the Department of Cardiovascular Surgery, Methodist DeBakey Heart & Vascular Center.

rupture, or deaths have yet been encountered.²² Other groups have reported similar findings. A recent study of 74 patients showed that there were no significant differences in failures of hypogastric side branch deployment (2 of 32) compared with hypogastric coiling (3 of 42). Reintervention rates were similar, but buttock claudication and impotence were more frequent after hypogastric exclusion.²³ Side branch endografting for iliac aneurysm may be considered a primary choice in younger, active patients with suitable anatomy.

Arch of the Aorta

The arch of the aorta poses unique problems for endografts, with both anatomic and hemodynamic conditions that are much different than those found in the descending visceral and infrarenal aorta. In general, debranching of the aorta has been used to facilitate placement of an endograft (Figure 5).²⁴⁻²⁶ A recent report of 11 patients who underwent urgent thoracic endovascular aortic repair (TEVAR) combined with a chimney graft demonstrated immediate technical success and good short-term outcomes.²⁷ A second report described a double-barrel stent technique used to maintain aortic arch branch vessel patency during TEVAR as technically successful, with maintenance of branch vessel patency and absence of type I endoleak.²⁸ Single-branch thoracic aortic endografts have been developed as a simpler, safer, and more effective means of treating aortic dissections, with entry tears in proximity to the left subclavian artery. In 16 patients, branched endografts deployed to seal the entry tear of a Stanford type B dissection had a 94% technical success rate. No paraplegia or distal organ or limb ischemia was noted, nor were there any mortalities or complications. By 3 months post-treatment, symptoms had abated, thrombosis had formed in the false lumen, and the true lumen had resumed its normal diameter in 15 of the 16 stent-graft patients.²⁹

Conclusion

Fenestrated and branched endografts offer us the bridge to the next frontier of aortic surgery. Once endovascular therapies can successfully negotiate the branches of the aorta and maintain patency, complete endografting of the aorta will be possible, and the need for open surgery will be significantly curtailed.

References

1. Estrera AL, Miller CC 3rd, Chen EP, Meada R, Torres RH, Porat EE, et al. Descending thoracic aortic aneurysm repair: 12-year experience using distal aortic perfusion and cerebrospinal fluid drainage. *Ann Thorac Surg.* 2005 Oct;80(4):1290-6.
2. Hirsch AT, Haskal ZJ, Hertzner NR, Bakal CW, Creager MA, Halperin JL, et al; American Association for Vascular Surgery; Society for Vascular Surgery; Society for Cardiovascular Angiography and Interventions; Society for Vascular Medicine and Biology; Society of Interventional Radiology; ACC/AHA Task Force on Practice Guidelines Writing Committee to Develop Guidelines for the Management of Patients With Peripheral Arterial Disease; American Association of Cardiovascular and Pulmonary Rehabilitation; National Heart, Lung, and Blood Institute; Society for Vascular Nursing; TransAtlantic Inter-Society Consensus; Vascular Disease Foundation. ACC/AHA 2005 Practice Guidelines for the management of patients with peripheral arterial disease (lower extremity, renal, mesenteric, and abdominal aortic): a collaborative report from the American Association for Vascular Surgery/Society for Vascular Surgery, Society for Cardiovascular Angiography and Interventions, Society for Vascular Medicine and Biology, Society of Interventional Radiology, and the ACC/AHA Task Force on Practice Guidelines (Writing Committee to Develop Guidelines for the Management of Patients With Peripheral Arterial Disease): endorsed by the American Association of Cardiovascular and Pulmonary Rehabilitation; National Heart, Lung, and Blood Institute; Society for Vascular Nursing; TransAtlantic Inter-Society Consensus; and Vascular Disease Foundation. *Circulation.* 2006 Mar 21;113(11):e463-654.
3. Svensson LG, Kouchoukos NT, Miller DC, Bavaria JE, Coselli JS, Curi MA, et al; Society of Thoracic Surgeons Endovascular Surgery Task Force. Expert consensus document on the treatment of descending thoracic aortic disease using endovascular stent-grafts. *Ann Thorac Surg.* 2008 Jan;85 (1 Suppl):S1-41.
4. Malkawi AH, Hinchliffe RJ, Holt PJ, Loftus IM, Thompson MM. Percutaneous access for endovascular aneurysm repair: a systematic review. *Eur J Vasc Endovasc Surg.* 2010 Jun;39(6):676-82. Epub 2010 Feb 24.
5. Chambers D, Epstein D, Walker S, Fayter D, Paton F, Wright K, et al. Endovascular stents for abdominal aortic aneurysms: a systematic review and economic model. *Health Technol Assess.* 2009 Oct;13(48):1-189, 215-318, iii.
6. Hiratzka LF, Bakris GL, Beckman JA, Bersin RM, Carr VF, Casey DE Jr, et al; American College of Cardiology Foundation/American Heart Association Task Force on Practice Guidelines; American Association for Thoracic Surgery; American College of Radiology; American Stroke Association; Society of Cardiovascular Anesthesiologists; Society for Cardiovascular Angiography and Interventions; Society of Interventional Radiology; Society of Thoracic Surgeons; Society for Vascular Medicine. 2010 ACCF/AHA/AATS/ACR/ASA/SCA/SCAI/SIR/STS/SVM guidelines for the diagnosis and management of patients with Thoracic Aortic Disease: a report of the American College of Cardiology Foundation/American Heart Association Task Force on Practice Guidelines, American Association for Thoracic Surgery, American College of Radiology, American Stroke Association, Society of Cardiovascular Anesthesiologists, Society for Cardiovascular Angiography and Interventions, Society of Interventional Radiology, Society of Thoracic Surgeons, and Society for Vascular Medicine. *Circulation.* 2010 Apr 6;121(13):e266-369.
7. Hiramoto JS, Chang CK, Reilly LM, Schneider DB, Rapp JH, Chuter TA. Outcome of renal stenting for renal artery coverage during endovascular aortic aneurysm repair. *J Vasc Surg.* 2009 May;49(5):1100-6.

8. Ohrlander T, Sonesson B, Ivancev K, Resch T, Dias N, Malina M. The chimney graft: a technique for preserving or rescuing aortic branch vessels in stent-graft sealing zones. *J Endovasc Ther.* 2008 Aug;15(4):427-32.
9. Rodd CD, Desigan S, Cheshire NJ, Jenkins MP, Hamady M. The suitability of thoraco-abdominal aortic aneurysms for branched or fenestrated stent grafts — and the development of a new scoring method to aid case assessment. *Eur J Vasc Endovasc Surg.* 2011 Feb;41(2):175-85. Epub 2010 Dec 3.
10. Greenberg RK, Haulon S, O'Neill S, Lyden S, Ouriel K. Primary endovascular repair of juxtarenal aneurysms with fenestrated endovascular grafting. *Eur J Vasc Endovasc Surg.* 2004 May;27(5):484-91.
11. O'Neill S, Greenberg RK, Haddad F, Resch T, Sereika J, Katz E. A prospective analysis of fenestrated endovascular grafting: intermediate-term outcomes. *Eur J Vasc Endovasc Surg.* 2006 Aug;32(2):115-23. Epub 2006 Mar 31.
12. Bicknell CD, Cheshire NJ, Riga CV, Bourke P, Wolfe JH, Gibbs RG, et al. Treatment of complex aneurysmal disease with fenestrated and branched stent grafts. *Eur J Vasc Endovasc Surg.* 2009 Feb;37(2):175-81.
13. Verhoeven EL, Vourliotakis G, Bos WT, Tielliu IF, Zeebregts CJ, Prins TR, et al. Fenestrated stent grafting for short-necked and juxtarenal abdominal aortic aneurysm: an 8-year single-centre experience. *Eur J Vasc Endovasc Surg.* 2010 May;39(5):529-36.
14. Muhs BE, Verhoeven EL, Zeebregts CJ, Tielliu IF, Prins TR, Verhagen HJ, et al. Mid-term results of endovascular aneurysm repair with branched and fenestrated endografts. *J Vasc Surg.* 2006 Jul;44(1):9-15.
15. Kienz P, Austermann M, Tessarek J, Torsello G. [Treatment of complex aortic aneurysms with fenestrated endografts - first results]. *Zentralbl Chir.* 2010 Oct;135(5):427-32. [Article in German]
16. Greenberg RK, Sternbergh WC 3rd, Makaroun M, Ohki T, Chuter T, Bharadwaj P, et al; Fenestrated Investigators. Intermediate results of a United States multicenter trial of fenestrated endograft repair for juxtarenal abdominal aortic aneurysms. *J Vasc Surg.* 2009 Oct;50(4):730-737.e1.
17. Haulon S, Amiot S, Magnan PE, Becquemin JP, Lermusiaux P, Koussa M, et al; Association Universitaire de Recherche en Chirurgie Vasculaire (AURC). An analysis of the French multicentre experience of fenestrated aortic endografts: medium-term outcomes. *Ann Surg.* 2010 Feb;251(2):357-62.
18. Sweet MP, Hiramoto JS, Park KH, Reilly LM, Chuter TA. A standardized multi-branched thoracoabdominal stent-graft for endovascular aneurysm repair. *J Endovasc Ther.* 2009 Jun;16(3):359-64.
19. Park KH, Hiramoto JS, Reilly LM, Sweet M, Chuter TA. Variation in the shape and length of the branches of a thoracoabdominal aortic stent graft: implications for the role of standard off-the-shelf components. *J Vasc Surg.* 2010 Mar;51(3):572-6.
20. Ziegler P, Avgerinos ED, Umscheid T, Perdikides T, Erz K, Stelter WJ. Branched iliac bifurcation: 6 years experience with endovascular preservation of internal iliac artery flow. *J Vasc Surg.* 2007 Aug;46(2):204-10.
21. Karthikesalingam A, Hinchliffe RJ, Holt PJ, Boyle JR, Loftus IM, Thompson MM. Endovascular aneurysm repair with preservation of the internal iliac artery using the iliac branch graft device. *Eur J Vasc Endovasc Surg.* 2010 Mar;39(3):285-94.
22. Ferreira M, Monteiro M, Lanzotti L. Technical aspects and midterm patency of iliac branched devices. *J Vasc Surg.* 2010 Mar;51(3):545-50.
23. Verzini F, Parlani G, Romano L, De Rango P, Panuccio G, Cao P. Endovascular treatment of iliac aneurysm: Concurrent comparison of side branch endograft versus hypogastric exclusion. *J Vasc Surg.* 2009 May;49(5):1154-61.
24. Zhou W, Reardon M, Peden EK, Lin PH, Lumsden AB. Hybrid approach to complex thoracic aortic aneurysms in high-risk patients: surgical challenges and clinical outcomes. *J Vasc Surg.* 2006 Oct;44(4):688-93.
25. Younes HK, Davies MG, Bismuth J, Naoum JJ, Peden EK, Reardon MJ, et al. Hybrid thoracic endovascular aortic repair: pushing the envelope. *J Vasc Surg.* 2010 Jan;51(1):259-66.
26. Patel R, Conrad MF, Paruchuri V, Kwolek CJ, Chung TK, Cambria RP. Thoracoabdominal aneurysm repair: hybrid versus open repair. *J Vasc Surg.* 2009 Jul;50(1):15-22.
27. Sugiura K, Sonesson B, Akesson M, Björnses K, Holst J, Malina M. The applicability of chimney grafts in the aortic arch. *J Cardiovasc Surg (Torino).* 2009 Aug;50(4):475-81.
28. Baldwin ZK, Chuter TA, Hiramoto JS, Reilly LM, Schneider DB. Double-barrel technique for preservation of aortic arch branches during thoracic endovascular aortic repair. *Ann Vasc Surg.* 2008 Nov;22(6):703-9.
29. Wang ZG, Li C. Single-branch endograft for treating Stanford type B aortic dissections with entry tears in proximity to the left subclavian artery. *J Endovasc Ther.* 2005 Oct;12(5):588-93