



J.J. Naoum, M.D.

THE CURRENT STATUS OF ENDOVASCULAR REPAIR OF ABDOMINAL AORTIC ANEURYSMS (EVAR)

Joseph J. Naoum, M.D.; Nyla Ismail, Ph.D.; Eric K. Peden, M.D.

Methodist DeBakey Heart & Vascular Center, The Methodist Hospital, Houston, Texas

Abstract

Abdominal aortic aneurysms (AAA) affect close to a quarter of a million people in the United States every year. Intervention is designed to treat the AAA when the patient becomes symptomatic and to prevent the fatality associated with rupture. Physicians and patients should weigh the risks associated with intervention compared to the risk of rupture for the particular size of the aneurysm and the patient's comorbidities. Thus, the decision to intervene, especially in asymptomatic aneurysms, is mostly based on clinical judgment. Endovascular AAA repair (EVAR) is attractive in that it offers a minimally invasive approach that obviates a major abdominal procedure and cross-clamping of the aorta. We report on the current affairs of the major clinical trials evaluating the outcomes of patients undergoing EVAR and describe the current devices available in the United States for endovascular repair.

Randomized Trials and EVAR

The DREAM trial randomized 351 patients to address the 2-year outcome after conventional or endovascular repair of >5 cm AAA and found that the cumulative rates of aneurysm-related perioperative death were 5.7% for open repair and 2.1% for EVAR. This survival advantage was not sustained after the first postoperative year.¹

Similarly, the OVER trial randomized 444 patients to EVAR and 437 patients to open surgical repair; all were considered to be candidates for both interventions. The 30-day mortality was 0.5% for EVAR compared to 3% for open repair. At 2 years follow-up, mortality was not significantly different for EVAR (7%) compared to open surgical repair (9.8%). Endovascular repair was associated with reduced median procedure time, blood transfusion requirements, duration of mechanical ventilation, and intensive care unit and hospital stays. There were no differences in major morbidity, secondary therapeutic procedures, or health-related quality of life (HRQL) scores. The authors concluded that longer-term data was needed to evaluate the outcomes of the two procedures. Thus, an interim report will follow at the 9-year trial mark.²

The EVAR 1 trial compared EVAR to open AAA repair in patients 60 years or older who had an AAA ≥ 5.5 cm and who were also fit for conventional open surgical repair. Between 1999 and 2003, 543 patients were randomized to EVAR and 539 to open repair. The 30-day mortality significantly differed for EVAR and open repair (1.7% compared to 4.7%, respectively). However, secondary interventions undertaken within 30 days of the procedure were significantly higher in the EVAR group (9.8%) compared to the open group (5.8%).³ The long-term results of this trial were further investigated past the initial 30-day mortality benefit of endovascular repair. Following 1 year, the HRQL was similar for patients in both groups. After 4 years of follow-up there was a similar 28% mortality for both groups that was associated with a persistent and yet lower aneurysm-related mortality for the EVAR group. At 4 years, EVAR did not offer an advantage in long-term all-cause mortality or HRQL, mandated ongoing surveillance,

and led to a greater number of complications and reinterventions, making it more expensive.⁴ After 8 years, the aneurysm-related survival was 93% in both groups while graft-related complications and reinterventions remained higher with endovascular repair.⁵

Unlike the previous trial, the EVAR 2 trial evaluated whether EVAR improved survival in similar patients who were not fit for open surgical repair of their AAA. Patients enrolled had significantly worse health than those studied in the EVAR 1 trial. Patients were randomized, and 166 were treated with EVAR while 172 had no intervention. Death from aneurysm rupture at 30 days in the no-intervention group was 9% and was similar to the 30-day mortality in the treatment group. All-cause mortality at 4 years was 64% for both groups without a difference in aneurysm-related mortality. Similar to the EVAR 1 trial, hospital costs for patients treated were higher without a difference in HRQL scores. Obscuring the data, more than a quarter of patients assigned to the no-intervention group underwent repair, one-third of them doing so because of patient preference. However, these crossovers did not alter the main conclusion of the trial that EVAR had a considerable 30-day operative mortality in patients already unfit for open repair of their aneurysm, did not improve survival over no intervention, and was associated with a need for continued surveillance and reinterventions at substantially increased cost.⁶ At the 8-year follow-up, the aneurysm-related mortality in the EVAR group was lower. However, this did not result in a difference in overall mortality. A total of 48% of patients had complications related to the EVAR, and 27% of those patients required reintervention, adding to the increased cost of the procedure compared to the no-intervention group.⁷

In essence, these trials demonstrated that for AAAs >5 cm, EVAR reduces 30-day aneurysm-related mortality and is associated with a lower length of hospital stay and related surgical benefits from a less morbid procedure. The data on longer-term benefits of EVAR compared to open repair is less clear, with no obvious survival advantage and an expense of continued surveillance, increased reintervention rates, and additional costs.

Small Aneurysm Trials and EVAR

To determine if EVAR is safe in the treatment of small AAAs, the CAESAR trial randomized patients >50 years of age with an AAA between 4.1–5.4 cm to receive immediate EVAR or surveillance by ultrasound and computed tomography. Repair in the surveillance group was performed if the AAA diameter reached ≥ 5.5 cm, the diameter increased >1 cm/year, or the patient became symptomatic. Between 2004 and 2008, 182 patients were randomized to EVAR and 178 to surveillance. The authors found that mortality and rupture rates in AAAs <5.5 cm were low and could not demonstrate a clear advantage between the early or delayed strategy. However, approximately 60% of the small aneurysms under surveillance grew to require repair within a 36-month period. Interestingly, the authors found that approximately 17% may lose feasibility for EVAR during this period. The authors conclude that EVAR is safe for small AAAs if close supervision is performed.⁸

In a similar manner, the PIVOTAL trial was organized to determine whether early EVAR reduced the risk of rupture or early aneurysm-related death compared with surveillance in patients between 40–90 years of age and with AAA size between 4–5 cm. This trial had 366 patients randomized to EVAR and 362 to surveillance for a mean follow-up period of 20 ± 12 months. During this study period, 30% of the patients in the surveillance group underwent EVAR — 70.6% for growth of the aneurysm, 11% due to request for repair, and 7.4% for the development of symptoms. The rate of perioperative mortality was 0.6%, and the 3-year rate of rupture was zero, surprisingly. The lower-than-expected rate of rupture prompted early termination but with the commitment to follow currently enrolled patients. Until longer-term data becomes available from this study, close surveillance and treatment with EVAR as clinically indicated appears as safe as EVAR for the small aneurysms in this trial.⁹ These studies suggest that in patients with small aneurysms, careful and close monitoring and surveillance is safe and will detect those who become symptomatic and those who demonstrate an increase in aneurysm size and require repair.

EVAR and Advanced Age

Fonseca and colleagues¹⁰ compared the periprocedural and late EVAR outcomes in 117 octogenarians to 205 patients younger than 80 years of age who underwent treatment over a 5-year period. The octogenarians were significantly more likely to have diabetes, coronary artery disease, chronic obstructive pulmonary disease, and renal insufficiency. There were no significant differences in

the rates of perioperative myocardial infarction, stroke, death, or arterial ischemic complications between this high-risk medical group and the younger cohort. However, octogenarians had a higher rate of access site hematomas, pulmonary problems, and other perioperative complications. Interestingly, the younger patients were twice as likely to develop a type II endoleak.

In a report by Goldstein and associates,¹¹ 24 patients >90 years of age who had an AAA were treated with EVAR. Perioperative mortality was 4.2% based on one patient, and there were no aneurysm-related deaths beyond the 30-day period. The authors conclude that with or without symptoms, patients over 90 years of age should be considered for EVAR. Despite their advanced age, patients benefit with a low morbidity and mortality and mean survival exceeding 2.4 years, especially in those with few comorbidities. These studies suggest that elderly patients >80 years of age with AAA, reasonable life expectancy, and adequate anatomy should be considered for EVAR. Though postoperative complications are higher than in younger cohorts, the morbidity of open AAA repair remains higher.

Endograft Devices in the United States

Since their initial design, endograft devices have undergone device redesigns and improvements to address sealing, fixation, migration, kink, and iliac access and to expand their aortic treatment indications. The following constitutes a concise description of the current state of commercially available AAA endografts in the United States (Table 1).

The AneuRx™ (Medtronic, Inc., Minneapolis, MN) modular bifurcated stent graft has a self-expanding nitinol skeleton that supports a woven polyester fabric (Figure 1). The diamond-shaped nitinol rings that comprise the exoskeleton provide the high radial strength required to achieve infrarenal fixation without active anchoring barbs. The delivery device has a hydrophilic coating designed to ease the delivery system's passage through tight and tortuous arteries by reducing friction with the arterial wall. The main body of the device is available in diameters of 20–28 mm and iliac limbs of 12–24 mm. The device is MRI conditional up to 3 Tesla.

The Excluder™ (W.L. Gore & Associates, Inc., Flagstaff, AZ) modular bifurcated stent graft is composed of a self-expanding nitinol wire construct with helical configuration that supports an expanded polytetrafluoroethylene (ePTFE) and fluorinated ethylene propylene (FEP) graft (Figure 2). The endograft carries nitinol anchors at the proximal edge that participate in active infrarenal

Table 1. Characteristics of commercially available AAA endografts in the United States.

Device	Maker	FDA Approval	Bifurcated Design	Stent Material	Fabric	Active Fixation	Suprarenal Fixation	MRI Conditional
AneuRx™	Medtronic, Inc.	1999	Modular	Nitinol	Polyester	No	No	Yes
Excluder™	W.L. Gore & Associates, Inc.	2002	Modular	Nitinol	ePTFE	Yes	No	Yes
Zenith™	Cook Medical, Inc.	2003	Modular	Stainless Steel	Polyester	Yes	Yes	Yes
Powerlink™	Endologix	2004	Unibody	Cobalt-Chromium	ePTFE	No	No	Yes
Talent™	Medtronic, Inc.	2008	Modular	Nitinol	Polyester	No	Yes	Yes
Endurant™	Medtronic, Inc.	2010	Modular	Nitinol	Polyester	Yes	Yes	Yes




Figure 1. The AneurRx™ (Medtronic, Inc., Minneapolis, MN) is constructed with woven polyester and self-expanding nitinol (nickel-titanium) alloy stent rings. Each ring has a series of diamond-shaped segments and broad proximal and distal sealing areas to accommodate longer aortic bodies, longer and larger straight iliac limbs, and flared iliac limbs and that comprise the exoskeleton. The AneurRx™ device also has the Xcelerant® Hydro Delivery System designed to ease the delivery system's passage through tight and tortuous arteries.




Figure 2. The Excluder™ (W.L. Gore & Associates, Inc., Flagstaff, AZ) is constructed from durable ePTFE bifurcated graft with an outer self-expanding nitinol support structure to combine both device flexibility and material durability. The device is inserted by a catheter-based delivery technique. The endograft carries nitinol anchors at the proximal edge that participate in active infrarenal fixation to resist migration and an ePTFE FEP sealing cuff at the same end.

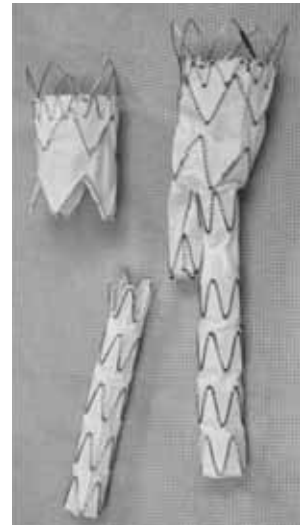


Figure 5. The Talent™ (Medtronic, Inc., Minneapolis, MN) consists of a fabric tube supported by a metal frame, and each graft is compressed into a long, thin, tube-like device to aid in deployment. The proximal end has bare springs allowing for suprarenal fixation that depends on the device's radial force component. The delivery device has a hydrophilic coating designed to ease the delivery system's passage through tight and tortuous arteries by reducing friction with the arterial wall; once deployed, it self-expands to the diameter of the aorta.

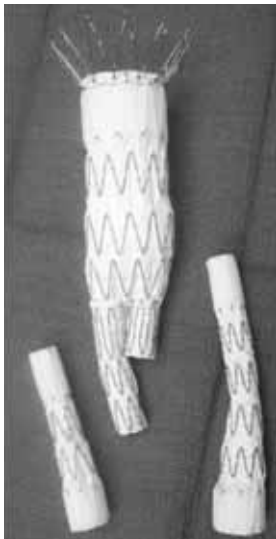


Figure 3. The Zenith Flex™ (Cook Medical, Inc., Bloomington, IN) is a modular bifurcated stent graft constructed with woven polyester Dacron that has a kink-resistant sheath and is composed of stainless steel stents. It uses a trigger-wire release mechanism during graft deployment and anchoring barbs to stabilize the graft to the aortic wall. The trigger-wire system also allows repositioning even when the device is partially deployed.

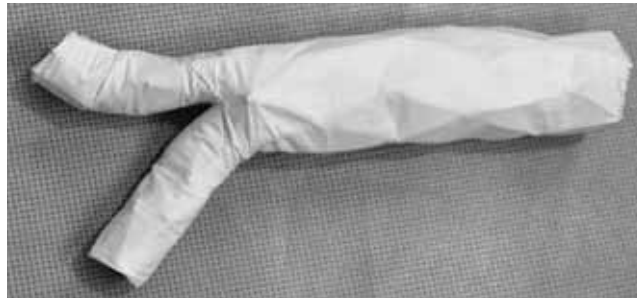


Figure 4. The Powerlink™ (Endologix, Irvine, CA) is created with self-expanding cobalt-chromium stents that form the inner structure. Aortic seal is achieved by radial force attained by the expanded endografts, while fixation is achieved by the graft sitting on the aortic bifurcation.




Figure 6. The Endurant™ (Medtronic, Inc., Minneapolis, MN) abdominal stent graft is a modular bifurcated system comprised of nitinol M-shaped stents attached to a high-filament polyester fabric most recently approved for use in the United States. Like other grafts, Endurant™ possesses suprarenal fixation along with stent anchoring pins.

fixation to resist migration and an ePTFE FEP sealing cuff at the same end. The main body of the device is available in diameters of 23–31 mm and iliac limbs of 10–20 mm. The device is MRI conditional up to between 1.5–3 Tesla.

The Zenith Flex™ (Cook Medical, Inc., Bloomington, IN) is a modular bifurcated stent graft constructed with a frame of self-expanding stainless steel Z-stents that are sewn to woven polyester Dacron grafts (Figure 3). The endograft has a suprarenal bare stent containing anchoring barbs for active fixation to resist migration. The main body is available in diameters between 22–36 mm and iliac limbs of between 8–24 mm. The device is MRI conditional up to 3 Tesla.

The Powerlink™ (Endologix, Irvine, CA) bifurcated unibody stent graft is created with self-expanding cobalt-chromium stents that form the inner structure of the device that supports an ePTFE graft (Figure 4). Aortic seal is achieved through radial force from the expanded endograft while fixation is achieved by the graft sitting on the aortic bifurcation. The main body of the device is manufactured in sizes ranging from 25–28 mm in diameter. The iliac limbs are 16 mm in diameter with extension limbs available

between 16–25 mm in diameter. The device is MRI conditional up to between 1.5–3 Tesla.

The Talent™ (Medtronic, Inc., Minneapolis, MN) abdominal stent graft is a modular bifurcated system comprised of nitinol springs attached to a polyester fabric material (Figure 5). The proximal end has bare springs, allowing for suprarenal fixation that depends on the device's radial force component. The delivery device has a hydrophilic coating designed to ease the delivery system's passage through tight and tortuous arteries by reducing friction with the arterial wall. The main body of the device is available in diameters of 22–36 mm and iliac limbs of 8–24 mm. The device is MRI conditional up to 3 Tesla.

The Endurant™ (Medtronic, Inc., Minneapolis, MN) abdominal stent graft is a modular bifurcated system comprised of nitinol M-shaped stents attached to a high filament polyester fabric most recently approved for use in the United States (Figure 6). Similar to the Zenith Flex endograft, Endurant™ possesses suprarenal fixation along with stent anchoring pins. The main body is available in diameters between 23–36 mm and iliac limbs of 10–28 mm. The device is MRI conditional up to 3 Tesla.

Conclusion

EVAR has rapidly emerged as the preferred treatment for AAAs at many medical centers in the United States, a remarkable shift considering that the first aortic endografts were approved in 1999. The low morbidity, shortened recovery time, and lower perioperative mortality have propelled this treatment to the forefront. Review of the available data suggests that there is an early mortality benefit that fades over time and a higher need for secondary procedures. Nonetheless, when presented with the options of endovascular repair versus the invasiveness of open repair, patients largely will choose the less-invasive option. The endografts continue to evolve to overcome many of their initial difficulties. Current devices vary considerably in their properties and offer lower profile, hydrophilic delivery systems, greater flexibility, improved methods of fixation, and a greater range of sizes. The problems of Type 2 endoleak and need for secondary intervention continue to challenge endograft outcomes, as does the need for lifetime surveillance. As the endografts develop further with next-generation devices, advances in these shortcomings are expected and will almost certainly lead to further widespread adoption of the treatment modality.

References

1. Blankensteijn JD, de Jong SE, Prinssen M, van der Ham AC, Buth J, van Sterkenburg SM, et al.; Dutch Randomized Endovascular Aneurysm Management (DREAM) Trial Group. Two-year outcomes after conventional or endovascular repair of abdominal aortic aneurysms. *N Engl J Med*. 2005 Jun 9;352(23):2398-405.
2. Lederle FA, Freischlag JA, Kyriakides TC, Padberg FT Jr, Matsumura JS, Kohler TR, et al.; Open Versus Endovascular Repair (OVER) Veterans Affairs Cooperative Study Group. Outcomes following endovascular vs open repair of abdominal aortic aneurysm: a randomized trial. *JAMA*. 2009 Oct 14;302(14):1535-42.
3. Grenhalgh RM, Brown LC, Kwong GP, Powell JT, Thompson SG; EVAR trial participants. Comparison of endovascular aneurysm repair with open repair in patients with abdominal aortic aneurysm (EVAR trial 1), 30-day operative mortality results: randomized controlled trial. *Lancet*. 2004 Sep 4-10;364(9437):843-8.
4. Grenhalgh RM, Brown LC, Kwong GP, Powell JT, Thompson SG; EVAR trial participants. Comparison of endovascular aneurysm repair with open repair in patients with abdominal aortic aneurysm (EVAR trial 1): randomized control trial. *Lancet*. 2005 Jun 25-Jul 1;365(9478):2179-86.
5. United Kingdom EVAR Trial Investigators, Greenhalgh RM, Brown LC, Powell JT, Thompson SG, Epstein D, Sculpher MJ. Endovascular versus open repair of abdominal aortic aneurysm. *N Engl J Med*. 2010 May 20;362(20):1863-71.
6. EVAR Trial Participants. Endovascular aneurysm repair and outcome in patients unfit for open repair of abdominal aortic aneurysm (EVAR trial 2): randomised controlled trial. *Lancet*. 2005 Jun 25-Jul 1;365(9478):2187-92.
7. United Kingdom EVAR Trial Investigators, Greenhalgh RM, Brown LC, Powell JT, Thompson SG, Epstein D. Endovascular repair of aortic aneurysm in patients physically ineligible for open repair. *N Engl J Med*. 2010 May 20;362(20):1872-80.
8. Cao P, De Rango P, Verzini F, Parlani G, Romano L, Cieri E; CAESAR Trial Group. Comparison of surveillance versus aortic endografting for small aneurysm repair (CAESAR): results from a randomised trial. *Eur J Vasc Endovasc Surg*. 2011 Jan;41(1):13-25.
9. Ouriel K, Clair DG, Kent KC, Zarins CK; Positive Impact of Endovascular Options for treating Aneurysms Early (PIVOTAL) Investigators. Endovascular repair compared with surveillance for patients with small abdominal aortic aneurysms. *J Vasc Surg*. 2010 May;51(5):1081-7.
10. Fonseca R, Rockman C, Pitti A, Cayne N, Maldonado TS, Lamparello PJ, et al. Intermediate-term EVAR outcomes in octogenarians. *J Vasc Surg*. 2010 Sep;52(3):556-60.
11. Goldstein LJ, Halpern JA, Rezayat C, Gallagher KA, Sambol EB, Bush HL Jr, et al. Endovascular aneurysm repair in nonagenarians is safe and effective. *J Vasc Surg*. 2010 Nov;52(5):1140-6.