

# Bioresorbable Coronary Scaffolds: Deployment Tips and Tricks and the Future of the Technology

*J. Ribamar Costa, Jr., M.D.<sup>a,b</sup>; Alexandre Abizaid, M.D.<sup>a,c</sup>*

<sup>a</sup>INSTITUTO DANTE PAZZANESE DE CARDIOLOGIA, SÃO PAULO, BRAZIL; <sup>b</sup>HOSPITAL DO CORAÇÃO (HCOR), SÃO PAULO, BRAZIL;

<sup>c</sup>HOSPITAL SÍRIO-LIBANÊS, SÃO PAULO, BRAZIL

**ABSTRACT:** Bioresorbable scaffolds (BRS) were developed as an alternative to drug-eluting stents (DES) to facilitate vessel restoration and reduce the risk of future adverse events. However, recent meta-analyses and “real-world” registries have raised some concern about the safety of this novel technology, especially due to an increased risk of thrombosis within the first weeks of scaffold implantation. These devices appear to be less forgiving to poor implantation strategies when compared to contemporary DES. Moreover, problems with the first generation of these devices—bulky struts and high crossing prolapse, prolonged resorption time, lack of x-ray visibility, and limited tolerance to postdilation—have restricted their clinical application and negatively impacted their short- to mid-term safety performance. However, the potential for long-term improvements has encouraged further research into strategies to overcome these limitations, and potentially safer next-generation devices are already undergoing in-human clinical evaluations. Based on the current literature and our center’s experience with these devices, this review discusses various approaches to optimize BRS implantation, drawbacks related to current-generation BRS, and potentially advantageous features of three next-generation scaffold systems.

## INTRODUCTION

Bioresorbable scaffolds (BRS) were developed as an alternative to drug-eluting stents (DES) to facilitate vessel restoration and reduce the risk of future adverse events. First-generation BRS are represented by the three CE-mark approved devices: the poly-L-lactic acid (PLLA)-based Absorb Bioresorbable Vascular Scaffold (Abbott Vascular) and DESolve NX (Elixir Medical) and the magnesium-based DREAMS (Biotronik) scaffold. Designed to overcome the drawbacks of DES—such as chronic local inflammatory reaction and late stent thrombosis—first-generation BRS have shown an efficacy profile comparable to second-generation metallic DES in low-to-moderate-complexity angiographic scenarios.<sup>1-6</sup> However, recent meta-analyses and “real-world” registries have raised some concern about the safety of this novel technology, especially due to an increased risk of thrombosis within the first weeks of scaffold implantation.<sup>7-10</sup> These devices appear to be less forgiving to poor implantation strategies when compared to contemporary DES. Additionally, first-generation BRS have several limitations, such as (1) increased strut thickness ( $\geq 150$   $\mu$ m) and crossing profile; (2) relatively low resistance to overexpansion, which might result in scaffold fracture; (3) lack of radiopacity, which requires a more frequent need for intravascular imaging modalities such as intravascular ultrasound (IVUS) and optical coherence tomography (OCT) to achieve reasonable device deployment; and (4) special storage requirements, such as refrigeration, to preserve the polymer physical characteristics.

It should be noted that consistent optimized implantation strategies were not used in most of the prior reports and they had relatively low rates of postdilation and intravascular imaging use.<sup>11-14</sup> Furthermore, a recent report demonstrated that the incidence of scaffold thrombosis could be significantly reduced with an optimal implantation strategy.<sup>15</sup> Even so, the combination of poor safety results and the above-listed limitations recently led Abbott Vascular to halt production of the Absorb Bioresorbable Vascular Scaffold. Use of the remaining first-generation devices has also been reduced and limited to simple anatomies and clinical trials. However, the concept behind the development of fully absorbable devices remains encouraging, and novel devices to overcome the current limitations are being pursued.

Based on the current literature and our center’s experience with these devices, this review discusses the various tips and tricks to optimize BRS implantation, the pitfalls related to the current generation of BRS, and the potentially advantageous features of three next-generation scaffold systems (Fantom, DESolve CX, and Meres 100) that are advanced in their in-human clinical evaluations.

## TIPS AND TRICKS FOR ADEQUATE BRS IMPLANTATION

Recent studies have suggested that adverse events after BRS may be more frequent with either undersizing or oversizing the scaffold relative to the vessel diameter and with implantation in

small vessels and suboptimal angiographic results.<sup>15,16</sup> Due to intrinsic properties related to its design and composition, the deployment of BRS might require some caveats. This has led to the concept of “PSP” (optimal predilatation, vessel and device sizing, and postdilatation) to optimize BRS outcomes.<sup>17</sup>

Adequate lesion preparation is an essential component when implanting current BRS and is important for both scaffold delivery and optimal scaffold expansion. BRS have larger crossing profiles, inevitably resulting in reduced deliverability compared to metallic DES. Furthermore, current BRS have less radial strength than metallic stents, which may result in greater acute recoil<sup>18</sup> and inadequate scaffold expansion in insufficiently prepared lesions.<sup>19,20</sup> Therefore, predilatation should be considered mandatory.

Overexpansion of the BRS, especially the first-generation ones, runs the risk of structural disruption/fracture. This has already been described with the Absorb device, which was the most frequently implanted BRS in daily practice until late 2017, when the manufacturer halted sales.<sup>21</sup> Conversely, underexpanded scaffolds and those with incomplete strut apposition might put the patient at higher risk of negative events during follow-up, as described in different series of BRS failure.<sup>9,22</sup>

Currently, Absorb is only available in three diameters (2.5, 3.0, and 3.5 mm), and it is recommended for implantation in de novo coronary lesions with reference lumen diameters between  $> 2.5$  mm and  $< 3.8$  mm. Thus, the current version of this device was not designed to treat large vessels due to the risk of structural damage in case of expansion above the recommended dimensions. Although other scaffolds in bench evaluations have been shown to tolerate postdilatation with bigger balloon catheters,<sup>23</sup> the safety of these procedures has not been properly addressed in a real-world clinical scenario since the inclusion criteria in trials evaluating these devices have been very restrictive to prevent this kind of situation.

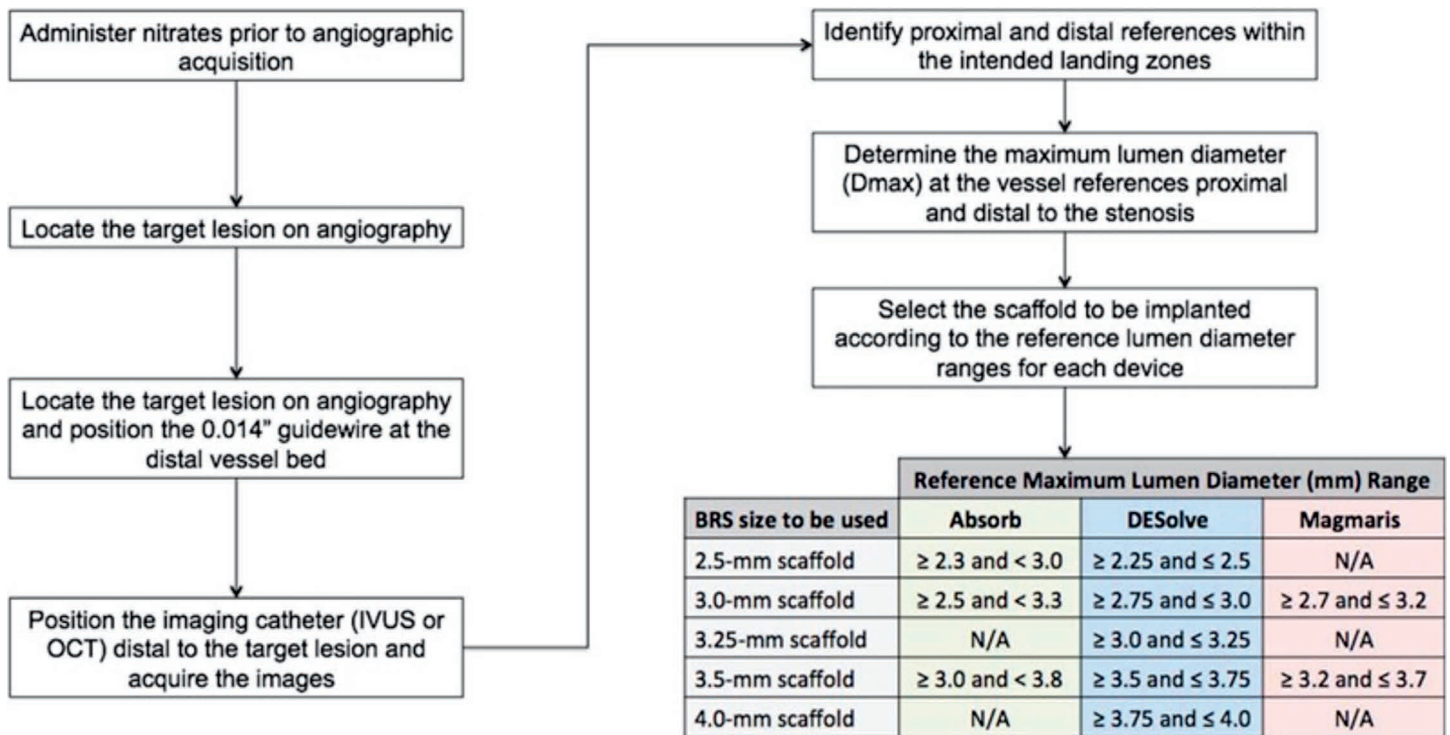
After publication of the ABSORB III trial, the use of these devices has been questioned for small vessels. In that study, BRS deployment in vessels with a reference diameter  $< 2.25$  mm resulted in increased rates of target lesion failure (12.9% vs 8.3%) and device thrombosis (4.6% vs 1.5%) when compared to metallic DES.<sup>2</sup> Part of this problem might be explained by their bulky struts (150 x 190 mm) limiting/disturbing the effective flow area in small coronary lumens. Reducing the strut surface in contact with the vessel wall can be achieved by reducing the strut size and/or modifying the strut shape. Plaque composition and high-pressure scaffold implantation may also play a role in strut embedment and ultimately influence the flow dynamic in the scaffolded segment. Postdilatation with a high-pressure balloon, within the device's expansion limits, may help

obtain a better strut embedment. Furthermore, recent studies have suggested that BRS implantation with high-pressure postdilatation rates (above 90%) and pressure (above 20 atm) are associated with lower rates of device thrombosis.<sup>24</sup>

In addition, while metallic stents have a smooth and antithrombogenic surface, the same electropolishing treatment cannot be applied to BRS polymeric scaffolds, which have a rough surface. Surface roughness influences the amount of protein adherence since it determines the contact area between the stent and coronary artery.<sup>25</sup> As such, the surface properties of the stent might influence post-PCI complications such as thrombogenicity and tissue reaction.<sup>26,27</sup> A smooth surface can help prevent the activation and aggregation of platelets, which is recognized as one component of the thrombosis process. Electropolishing effectively minimizes thrombosis and potentially reduces neointimal hyperplasia.<sup>28</sup>

Notably, visual estimation and online quantitative comparative analysis (QCA) are the most frequent tools to determine stent dimensions since they are usually available worldwide, require less-specific training, and do not add additional cost or time to the procedure. However, it is important to note that neither the Absorb device nor most BRS under clinical investigation are radiopaque; therefore, angiography is limited in identifying problems related to their deployment. The only exception is the Fantom BRS, which is developed from a proprietary, inherently radiopaque polymer composed of tyrosine analogs and other natural metabolites that allow visualization using conventional angiography. As a result, the advent of BRS has encouraged a more widespread use of intravascular imaging (IVUS/OCT) for a more accurate estimation of real vessel dimension and to identify potential mechanisms of device failure, including underexpansion, incomplete strut apposition, and structural device damage. Figure 1 illustrates our center's algorithm for BRS diameter selection based on preintervention intravascular imaging assessment. Even so, two recent surveys of operators experienced in BRS implantation indicated that they used routine intracoronary imaging in less than 20% of their cases.<sup>29,30</sup> Therefore, even in high-volume centers that treat complex lesions, device choice is mostly based on visual estimation ( $> 80\%$  of cases) or online QCA (14%),<sup>30</sup> which might explain the poorer outcomes reported with these devices in more cumbersome scenarios.

For postdilatation, an accurately-sized noncompliant balloon (1:1 scaffold:balloon diameter) with high pressure (more than 20 atm) can be an appropriate initial strategy. If further postdilatation is required, higher pressures with the same noncompliant balloon or a different balloon with a diameter equal to scaffold size (with a maximum of 0.5 mm) can be used. The threshold for scaffold fracture may decrease depending on



**Figure 1.** Algorithm for vessel sizing by intravascular imaging and scaffold selection based on target vessel reference lumen diameter. The maximum lumen diameter (Dmax) at the intended proximal and distal landing zones must fall within the lower and upper reference Dmax ranges recommended for each device. If the proximal and distal Dmax fall into different diameter ranges, the intended device should not be implanted. BRS: bioresorbable scaffold.

lesion morphology; therefore, inflation pressure should be carefully increased when using larger balloons.

**NEXT-GENERATION BIORESORBABLE SCAFFOLDS**


*DESolve*

The DESolve scaffold (Elixir Medical) is comprised of a PLLA-based backbone coated with a matrix of the

drug Novolimus and a polylactide-based polymer. The drug is contained in a proprietary bioresorbable PLLA-based polymer from the same family of PLLA-based polymers contained in the scaffold backbone. The device has sinusoidal ring patterns optimized for each diameter and requires two platinum-markers at each end to facilitate positioning and postdilation (Figure 2). Inflation should be performed gradually, increasing 2 atm every 3 to 5

seconds, and the device must be stored between 0°C and 8°C.

The antiproliferative drug Novolimus is a metabolite of sirolimus and belongs to the family of compounds of macrocyclic lactones with a mechanism of action similar to sirolimus. Novolimus is applied to the scaffold at a dose of 5 µg per mm of scaffold length, and 85% of the drug is eluted over 4 weeks.<sup>4</sup> The polymer coating degrades within 6 to 9 months,



**Figure 2.** The DESolve scaffold. This bioresorbable scaffold has sinusoidal ring patterns with an open-cell body optimized for each diameter; it is not radiopaque and requires two platinum markers at each end. Reprinted with permission.

and the PLLA-based scaffold degrades within 12 months and resorbs within 24 months.

A polymer's differing chemical properties and the way they are processed produce distinctive mechanical properties. As a result, the DESolve BRS has some unique features, including (A) the ability to self-correct to the vessel wall when expanded to nominal diameter and therefore to correct small incomplete strut apposition<sup>31</sup>; (B) the ability to tolerate overexpansion during postdilation without fracture<sup>23,31</sup> (e.g., a 3.0-mm scaffold has been shown to expand up to 4.5 mm with no structural damage); and (C) a shorter bioresorption time (95% reduction in molecular weight by 1 year, with complete absorption by 2 years).

The DESolve NX, the first generation of this BRS, has already received CE-mark approval. It has a strut thickness of 150  $\mu\text{m}$  and had its efficacy evaluated in the single-arm, multicenter DESolve NX trial, which enrolled 126 patients with noncomplex coronary lesions. Device success was achieved in 97% of the cases, and acute recoil was low (6.6%). A 6-month invasive assessment was obtained in 93% of the cases and showed in-scaffold and in-segment QCA late loss of  $0.20 \pm 0.32$  and  $0.21 \pm 0.31$  mm, respectively, with 3.5% binary restenosis.<sup>5</sup> Of note, in the IVUS ( $n = 40$ ) and OCT ( $n = 38$ ) substudies, this BRS showed an early and significant area increase from postprocedure to the 6-month follow-up that was attributed to its early resorption properties, which resulted in early vessel restoration. Additionally, at 6 months, 98.8% of all struts were fully covered by OCT with a very thin layer of tissue (30.6  $\mu\text{m}$ ). No case of scaffold thrombosis was documented in this registry.<sup>5</sup> More recently, DESolve has undergone a few alterations in polymer processing, resulting in a 20% reduction in strut thickness while maintaining its unique features. The novel DESolve CX (120  $\mu\text{m}$ ) is currently being evaluated in a first-in-man registry with 150 patients.

In parallel, Elixir Medical has developed a scaffold dedicated to STEMI patients. The Amity device has the same self-correction mechanism as DESolve and can expand up to 0.6 mm in diameter over 3 days, which may be useful for thrombus-containing lesions. Once the thrombus vanishes, the self-correction mechanism would then resolve any residual strut malapposition. Clinical evaluation of this device is yet to be initiated.


Finally, one of the drawbacks of current BRS is the limited variety of sizes available for commercial use. In particular, treatment of large coronary arteries has been curtailed by the lack of devices with diameters  $> 3.5$  mm. To this end, Elixir has recently developed a scaffold dedicated to the treatment of large vessels. The DESolve XL is a polylactic acid-based device with a nominal diameter of 4.0 mm and a strut thickness of 150  $\mu\text{m}$ , although additional device characteristics regarding polymer and antiproliferative drug kinetics are the same as those

of the other Elixir scaffolds. The first-in-man evaluation of this BRS was performed in 10 patients treated with 4.0- x 18-mm devices guided by OCT imaging.<sup>32</sup> On average, postdilation was performed with  $4.8 \pm 0.3$ -mm balloons. No case of scaffold fracture was noticed after the procedure, and the percentage of malapposed struts was only  $0.09 \pm 0.26\%$ .

### *Fantom*

A major drawback of most contemporary polymers is the lack of intrinsic radiopacity, which might result in "geographical miss" during implantation and require more use of intracoronary imaging to guide scaffold deployment. Recently, REVA Medical developed a proprietary, inherently radiopaque polymer composed of tyrosine analogs and other natural metabolites. The resulting copolymer is a biodegradable polyester carbonate called poly(I2DAT-co-lactic acid). Additionally, iodinated tyrosine analogues such as 3,5-di-iododesaminotyrosine were incorporated into the polymer backbone, which allows the device to be visualized using conventional angiography. Iodine atoms are covalently bound directly to the backbone of the desaminotyrosine component and, due to their greater mass, scatter x-rays and impart radiopacity.

Initial in-human studies with this polymer focused on an innovative "Slide & Lock" design as found in the ReZolve scaffold series. Unlike traditional deformable metal stent designs, the Slide & Lock design is deployed by sliding open and locking into place. It had a series of 15 individual components assembled into a single scaffold, and the components were made up of two primary elements that included 12 U-shaped 120- $\mu\text{m}$  struts and three sinusoidal backbone components of approximately 203  $\mu\text{m}$  thickness. In theory, this novel design would eliminate the need to significantly deform the device during deployment, making it ideally suited for use with polymers, which are inherently not as amenable to deformation as metals. However, technical difficulty related to its deliverability, documented scaffold fracture, and excessive neointimal tissue formation led the company to develop a second-generation device (the Fantom scaffold) using a traditional deformable design. The platform of the current version is a single-element device that contains a uniform thickness of approximately 125  $\mu\text{m}$  across the full length of the scaffold (Figure 3). Designed as circumferential supporting hoops, the scaffold is joined by a series of non-supporting connective elements, with a crossing profile of 1.25 to 1.35 mm depending on scaffold diameter (5F compatible).<sup>33</sup> Notably, the polymer backbone is manufactured to withstand single-step inflation during deployment, mimicking the traditional method of metallic stent expansion without fracture. The modulus of elasticity ranges from 2.0 to 2.4 GPa, while the tensile strength and elongation at break are 80 to 95 MPa



**Figure 3.**

The Fantom scaffold. (A) The Fantom bioresorbable scaffold (BRS), the current version of REVA's scaffold, shows the traditional deformable design that resulted in a significant reduction in strut thickness and crossing profile and improvement in device deliverability. (B) The combination polyestercarbonate polymer called poly (l2DAT-co-lactic acid) with 3,5-diiododesaminotyrosine grants x-ray visibility to this BRS.<sup>33</sup>

and > 150%, respectively. Thus, it is recommended that the postdilatation balloon not overstretch the scaffold by more than 0.75 mm. The Fantom BRS does not have any special storage requirements such as refrigeration.

The device backbone is coated with a thin layer of an amorphous form of the same polymer, which carries the antiproliferative drug sirolimus in a dose of 197  $\mu\text{g}/\text{cm}^2$ . This coating matrix promotes controlled release of sirolimus such that 60% of the total drug load is released within the first 30 days. The remaining sirolimus dose is released slowly over the next several months.

The polymer degrades via hydrolysis of the carbonate and ester bonds in the backbone, with the resulting l2DAT excreted through the kidneys and lactic acid metabolized through the Krebs cycle. According to preclinical studies, complete polymer backbone degradation is expected to occur at 36 to 48 months. The polymer-coating matrix is the same as the backbone polymer and is expected to degrade similarly.

A pilot human evaluation of this BRS was conducted in two centers (Brazil and Poland). Seven patients with single de novo lesions treated with 3.0- x 18-mm devices were enrolled in the FANTOM I trial.<sup>34</sup> Device success was achieved in all cases, with an acute recoil of 4.82%. At 4-month invasive follow-up, in-scaffold late loss was 0.21 mm while neointimal hyperplasia obstruction by IVUS was  $3.14\% \pm 2.04\%$ . Notably, OCT evaluation revealed that 99.1% of all scaffold struts were fully covered, with no single case of incomplete apposition.<sup>34</sup>

Following the enthusiastic initial results, the FANTOM II trial recruited 240 patients with up to two de novo lesions treatable

with devices of 2.5, 3.0, or 3.5 mm in diameter and up to 24 mm long. The enrolled population was divided into two cohorts with distinct invasive follow-up timelines. Cohort A (n = 117) underwent invasive follow-up at 6 and 24 months while cohort B (n = 123) underwent follow-up at 9 and 36 months. Short-term technical success, short-term procedural success, and clinical procedural success were achieved in 96.6%, 99.1%, and 99.1% of patients, respectively. Mean 6-month in-stent late lumen loss was  $0.25 \pm 0.40$  mm (n = 100). Binary restenosis was present in two patients (2.0%). Major adverse cardiac events within 6 months occurred in three patients (2.6%), including no deaths, two myocardial infarctions (MI), and two target lesion revascularizations (TLRs); one patient had both an MI and TLR, and scaffold thrombosis occurred in one patient (0.9%).<sup>35</sup>

#### MeRes 100

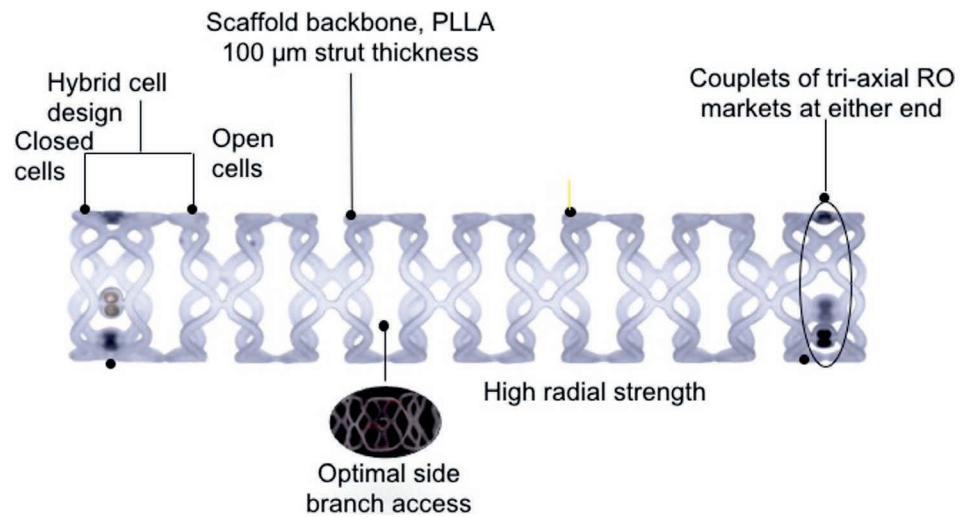
The MeRes100 BRS (Meril Life Sciences Pvt. Ltd.) is a balloon-expandable PLLA polymer backbone scaffold. The top contains an active drug coating of sirolimus distributed at a dose of 1.25  $\mu\text{g}/\text{mm}^2$  formulated in a 1:1 mixture of biocompatible and bioabsorbable polymer poly-D, L-lactide (PDLLA), which acts as a drug reservoir and controls the drug release rate. The thin uniform coating is 3 to 4  $\mu\text{m}$  and does not web, crack, or lump as studied by scanning electron microscopy. Both PLLA and PDLLA undergo hydrolytic degradation of the ester bonds in the polymers, generating lactic acid that is converted to  $\text{CO}_2$  and  $\text{H}_2\text{O}$ , which are eliminated from the body.

The expected degradation of the scaffold from the treatment site is within 24 to 36 months of implantation.<sup>36</sup> The MeRes100 BRS has a hybrid cell design, close cells at the edges, and

open cells along the length (Figure 4) to ensure optimal vessel wall conformability. It has a low strut thickness of 100  $\mu\text{m}$ , and strut width varies from 150 to 200  $\mu\text{m}$ , depending on scaffold diameters. The crossing profile is 1.20 mm and 1.25 mm for 3.0 mm and 3.5 mm diameters, respectively. The couplets of tri-axial platinum radiopaque markers fixed circumferentially 120° apart from each other at either end of the scaffold allow it to be viewed in two orthogonal views during its deployment.

In preclinical studies using OCT and histopathology, the MeRes100 showed equivalent in vivo acute and chronic recoil as well as similar neointimal formation and arterial healing up to 180 days when compared to the benchmark Absorb BRS up to 180 days. Preliminary evaluation of serial OCT obtained at 1 and 2 years suggests a more gradual integration of the scaffold into the arterial wall than that reported for Absorb (2% of preserved box appearance in MeRes100 vs 80.4% for Absorb at 2 years).

The MeRes-1 first-in-human trial was a single-arm prospective multicenter study that enrolled 108 patients with de novo coronary artery lesions (116 scaffolds were deployed to treat 116 lesions in 108 patients). At 6 months, quantitative coronary angiography revealed in-scaffold late lumen loss of  $0.15 \pm 0.23$  mm with 0% binary restenosis. Optical coherence tomography demonstrated minimum scaffold area ( $6.86 \pm 1.73$  mm<sup>2</sup>) and 99.30% neointimal strut coverage. Quantitative intravascular ultrasound analysis confirmed a  $0.14 \pm 0.16$  mm<sup>2</sup> neointimal hyperplasia area. At 1 year, major adverse cardiac events—a composite of cardiac death, any myocardial infarction, and ischemia-driven target lesion revascularization—occurred in only one patient (0.93%) and no scaffold thrombosis was reported. At 1 year, computed tomography angiography demonstrated that all scaffolds were



*Figure 4.*

The MeRes 100 scaffold. This bioresorbable scaffold has low strut thickness (100  $\mu\text{m}$ ) and a hybrid cell design. Couplets of tri-axial markers are positioned at either end to facilitate deployment and postdilation. Reprinted with permission.

#### KEY POINTS

- Bioresorbable scaffolds (BRS) were developed as an alternative to drug-eluting stents (DES) to facilitate vessel restoration and reduce the risk of future adverse events, but problems regarding safety and effectiveness of first-generation BRS have restricted their clinical use.
- Use of BRS should be avoided in coronary arteries  $< 2.5$  mm or  $> 4.0$  mm and carefully considered in complex anatomies and clinical scenarios—including aorto-ostial and long lesions, bifurcations, and patients with acute coronary syndrome (particularly acute STEMI).
- The advent of BRS has led to more widespread use of intravascular imaging (IVUS/OCT) for a more accurate estimation of real vessel dimension and to identify potential mechanisms of device failure; however, visual estimation and online qualitative comparative analysis are the most frequent tools to determine stent dimensions.
- Deployment of BRS requires optimal predilation, accurate vessel and device sizing, and postdilation to optimize outcomes.
- Second-generation BRS designed to overcome first-generation problems related to thrombosis, strut thickness, opacity, resorption time, and inadequate sizing are being developed and evaluated in clinical trials.

patent, and in-scaffold mean percentage area stenosis was  $11.33\% \pm 26.57\%$ .<sup>36</sup>

#### CONCLUSIONS

Despite the theoretical long-term benefits of bioresorbable scaffolds in

the treatment of coronary artery disease, the first generation of these devices—with bulky struts and high crossing prolapse, prolonged resorption time ( $> 24$  months), lack of x-ray visibility, and limited tolerance to postdilation—have restricted their clinical application and

negatively impacted their short- to mid-term safety performance, with a trend to more thrombotic events compared to the current generation of metallic drug-eluting stents. At present, BRS should be avoided in very large coronary arteries (> 4.0 mm) and carefully considered in complex anatomies and clinical scenarios, including aorto-ostial and long lesions, bifurcations, and patients with acute coronary syndrome, particularly those with acute STEMI. The future of this technology as a “working horse” in the interventional cardiology field depends on the clinical performance—supported by a stronger body of scientific data—of the next generation of these devices.

*Conflict of Interest Disclosure:*

Dr. Abizaid is a formal advisor for Boston Scientific Corp., Abbott, and Elixir Medical Corp.

*Keywords:*

bioresorbable scaffolds, drug-eluting stents, scaffold systems, vascular stents

**REFERENCES**

- Serruys PW, Chevalier B, Dudek D, et al. A bioresorbable everolimus-eluting scaffold versus a metallic everolimus-eluting stent for ischaemic heart disease caused by de-novo native coronary artery lesions (ABSORB II): an interim 1-year analysis of clinical and procedural secondary outcomes from a randomised controlled trial. *Lancet*. 2015 Jan 3;385(9962):43-54.
- Ellis SG, Kereiakes DJ, Metzger DC, et al.; ABSORB III Investigators. Everolimus-Eluting Bioresorbable Scaffolds for Coronary Artery Disease. *N Engl J Med*. 2015 Nov 12;373(20):1905-15.
- Abizaid A, Ribamar Costa J Jr, Bartorelli AL, et al; ABSORB EXTEND investigators. The ABSORB EXTEND study: preliminary report of the twelve-month clinical outcomes in the first 512 patients enrolled. *EuroIntervention*. 2015 Apr;10(12):1396-401.
- Verheye S, Ormiston JA, Stewart J, et al. A next-generation bioresorbable coronary scaffold system: from bench to first clinical evaluation: 6- and 12-month clinical and multimodality imaging results. *JACC Cardiovasc Interv*. 2014 Jan;7(1):89-99.
- Abizaid A, Costa RA, Schofer J, et al. Serial Multimodality Imaging and 2-Year Clinical Outcomes of the Novel DESolve Novolimus-Eluting Bioresorbable Coronary Scaffold System for the Treatment of Single De Novo Coronary Lesions. *JACC Cardiovasc Interv*. 2016 Mar 28;9(6):565-74.
- Haude M, Ince H, Abizaid A, et al. Safety and performance of the second-generation drug-eluting absorbable metal scaffold in patients with de-novo coronary artery lesions (BIOSOLVE-II): 6 month results of a prospective, multicentre, non-randomised, first-in-man trial. *Lancet*. 2016 Jan 2;387(10013):31-9.
- Stone GW, Gao R, Kimura T, et al. 1-year outcomes with the Absorb bioresorbable scaffold in patients with coronary artery disease: a patient-level, pooled meta-analysis. *Lancet*. 2016 Mar 26;387(10025):1277-89.
- Lipinski MJ, Escarcega RO, Baker NC, et al. Scaffold Thrombosis After Percutaneous Coronary Intervention With ABSORB Bioresorbable Vascular Scaffold: A Systematic Review and Meta-Analysis. *JACC Cardiovasc Interv*. 2016 Jan 11;9(1):12-24.
- Räber L, Brugaletta S, Yamaji K, et al. Very Late Scaffold Thrombosis: Intracoronary Imaging and Histopathological and Spectroscopic Findings. *J Am Coll Cardiol*. 2015 Oct 27;66(17):1901-14.
- Capodanno D, Gori T, Nef H, et al. Percutaneous coronary intervention with everolimus-eluting bioresorbable vascular scaffolds in routine clinical practice: early and midterm outcomes from the European multicentre GHOST-EU registry. *EuroIntervention*. 2015 Feb;10(10):1144-53.
- Wöhrle J, Naber C, Schmitz T, et al. Beyond the early stages: insights from the ASSURE registry on bioresorbable vascular scaffolds. *EuroIntervention*. 2015 Jun;11(2):149-56.
- Kraak RP, Hassell ME, Grundeken MJ, et al. Initial experience and clinical evaluation of the Absorb bioresorbable vascular scaffold (BVS) in real-world practice: the AMC Single Centre Real World PCI Registry. *EuroIntervention*. 2015 Feb;10(10):1160-8.
- Gori T, Schulz E, Hink U, et al. Clinical, Angiographic, Functional, and Imaging Outcomes 12 Months After Implantation of Drug-Eluting Bioresorbable Vascular Scaffolds in Acute Coronary Syndromes. *JACC Cardiovasc Interv*. 2015 May;8(6):770-777.
- Cortese B, Ielasi A, Romagnoli E, et al. Clinical Comparison With Short-Term Follow-Up of Bioresorbable Vascular Scaffold Versus Everolimus-Eluting Stent in Primary Percutaneous Coronary Interventions. *Am J Cardiol*. 2015 Sep 1;116(5):705-10.
- Puricel S, Cuculi F, Weissner M, et al. Bioresorbable Coronary Scaffold Thrombosis: Multicenter Comprehensive Analysis of Clinical Presentation, Mechanisms, and Predictors. *J Am Coll Cardiol*. 2016 Mar 1;67(8):921-31.
- Ishibashi Y, Nakatani S, Sotomi Y, et al. Relation Between Bioresorbable Scaffold Sizing Using QCA-Dmax and Clinical Outcomes at 1 Year in 1,232 Patients From 3 Study Cohorts (ABSORB Cohort B, ABSORB EXTEND, and ABSORB II). *JACC Cardiovasc Interv*. 2015 Nov;8(13):1715-26.
- Ortega-Paz L, Capodanno D, Gori T, et al. Predilation, sizing and post-dilation scoring in patients undergoing everolimus-eluting bioresorbable scaffold implantation for prediction of cardiac adverse events: development and internal validation of the PSP score. *EuroIntervention*. 2017 Apr 20;12(17):2110-2117.
- Danzi GB, Sesana M, Arieti M, et al. Does optimal lesion preparation reduce the amount of acute recoil of the Absorb BVS? Insights

- from a real-world population. *Catheter Cardiovasc Interv.* 2015 Nov 15;86(6):984-91.
19. Mattesini A, Secco GG, Dall'Ara G, et al. ABSORB biodegradable stents versus second-generation metal stents: a comparison study of 100 complex lesions treated under OCT guidance. *JACC Cardiovasc Interv.* 2014 Jul;7(7):741-50.
  20. Brown AJ, McCormick LM, Braganza DM, Bennett MR, Hoole SP, West NE. Expansion and malapposition characteristics after bioresorbable vascular scaffold implantation. *Catheter Cardiovasc Interv.* 2014 Jul 1;84(1):37-45.
  21. Onuma Y, Serruys PW, Muramatsu T, et al. Incidence and imaging outcomes of acute scaffold disruption and late structural discontinuity after implantation of the absorb Everolimus-Eluting fully bioresorbable vascular scaffold: optical coherence tomography assessment in the ABSORB cohort B Trial (A Clinical Evaluation of the Bioabsorbable Everolimus Eluting Coronary Stent System in the Treatment of Patients With De Novo Native Coronary Artery Lesions). *JACC Cardiovasc Interv.* 2014 Dec;7(12):1400-11.
  22. Sotomi Y, Suwannasom P, Serruys PW, Onuma Y. Possible mechanical causes of scaffold thrombosis: insights from case reports with intracoronary imaging. *EuroIntervention.* 2017 Feb 20;12(14):1747-56.
  23. Ormiston JA, Webber B, Ubod B, Darremont O, Webster MW. An independent bench comparison of two bioresorbable drug-eluting coronary scaffolds (Absorb and DESolve) with a durable metallic drug-eluting stent (ML8/Xpedition). *EuroIntervention.* 2015 May;11(1):60-7.
  24. Caiazzo G, Kilic ID, Fabris E, et al. Absorb bioresorbable vascular scaffold: What have we learned after 5 years of clinical experience? *Int J Cardiol.* 2015 Dec 15;201:129-36.
  25. Andrade JD, Hlady V. Plasma Protein Absorption: The Big Twelve. In: Leonard EF, Turitto VT, Vroman I, editors. *Blood in Contact with Natural and Artificial Surfaces: Annals of the New York Academy of Sciences.* New York: New York Academy of Sciences; 1987. p. 153.
  26. Wang K. Biocompatibilisation of Coronary Artery Stents. *Acta Biomedica Lovaniensia.* 1997;162:89-102.
  27. Steinemann SG. Metal implants and surface reactions. *Injury.* 1996;27 Suppl 3:SC16-22.
  28. de Scheerder I, Sohier J, Wang K. Metallic Surface Treatment Using Electrochemical Polishing Decreases Thrombogenicity and Neointimal Hyperplasia of Coronary Stents. *J Interv Cardiol.* 2000;13:179-85.
  29. Cortese B, Valgimigli M. Current know how on the absorb BVS technology: an experts' survey. *Int J Cardiol.* 2015 Feb 1;180:203-5.
  30. Tamburino C, Latib A, van Geuns RJ, et al. Contemporary practice and technical aspects in coronary intervention with bioresorbable scaffolds: a European perspective. *EuroIntervention.* 2015 May;11(1):45-52.
  31. Wiebe J, Bauer T, Dörr O, Möllmann H, Hamm CW, Nef HM. Implantation of a novolimus-eluting bioresorbable scaffold with a strut thickness of 100 µm showing evidence of self-correction. *EuroIntervention.* 2015 Jun;11(2):204.
  32. Boeder NF, Koepp T, Dörr O, et al. A new novolimus-eluting bioresorbable scaffold for large coronary arteries: an OCT study of acute mechanical performance. *Int J Cardiol.* 2016 Oct 1;220:706-10.
  33. CV Pipeline [Internet]. Santa Barbara, CA: Market Monitors, Inc.; c2018. Fantom, REVA Medical, Inc. [cited 2018 Jan 8]. Available from: <https://www.cvpipeline.com/sectors/DES/products>.
  34. Costa J, Abizaid A, Chamie D, Lansky A, Kochman J, Koltowski L. Initial results of the FANTOM I trial: a first-in-man evaluation of a novel, radiopaque sirolimus-eluting bioresorbable vascular scaffold. *J Am Coll Cardiol.* 2016;67(13S):232.
  35. Abizaid A, Carrié D, Frey N, et al.; FANTOM II Clinical Investigators. 6-Month Clinical and Angiographic Outcomes of a Novel Radiopaque Sirolimus-Eluting Bioresorbable Vascular Scaffold: The FANTOM II Study. *JACC Cardiovasc Interv.* 2017 Sep 25;10(18):1832-8.
  36. Seth A, Onuma Y, Costa R, et al. First-in-human evaluation of a novel poly-L-lactide based sirolimus-eluting bioresorbable vascular scaffold for the treatment of de novo native coronary artery lesions: MeRes-1 trial. *EuroIntervention.* 2017 Jul 20;13(4):415-423.