

---

# MITRAL VALVE SURGERY: CURRENT MINIMALLY INVASIVE AND TRANSCATHETER OPTIONS

Basel Ramlawi, M.D.<sup>a</sup>; James S. Gammie, M.D.<sup>b</sup>

<sup>a</sup>Valley Health System, Winchester, Virginia; <sup>b</sup>University of Maryland Hospital System, Baltimore, Maryland

---

## Abstract

The mitral valve is a highly complex structure, the competency and function of which relies on the harmonious action of its component parts. Minimally invasive cardiac surgery (MICS) for mitral valve repair or replacement (MVR/r) has been performed successfully with incremental improvements in techniques over the past decade. These minimally invasive procedures, while attractive to patients and referring physicians, should meet the same high bar for optimal clinical outcomes and long-term durability of valve repair as traditional sternotomy procedures. The majority of MICS MVR/r procedures are performed via a right minithoracotomy approach with direct or camera-assisted visualization, with a minority of centers performing robotic MVR/r. Outcomes with MICS MVR/r have been shown to have similar morbidity and mortality rates as traditional sternotomy MV procedures but with the advantage of reduced transfusions, postoperative atrial fibrillation, and time to recovery.

More recently, transcatheter mitral valve repair and replacement (TMVR/r) has become a reality. Percutaneous MV repair technology is currently FDA approved for patients with nonsurgical high-risk degenerative mitral regurgitation. Other TMVR/r technology is at various levels of preclinical and clinical investigation, although these devices are proving to be more challenging compared to transcatheter aortic valve replacement (TAVR) due to the significantly more complex mitral anatomy and the greater heterogeneity of mitral disease requiring treatment. In this article, we review current techniques for MICS MVR/r and upcoming catheter-based therapies for the mitral valve.

---

## Introduction

The mitral valve (MV) apparatus is an anatomically complex structure that includes the ventricle, papillary muscles, chordae tendinae, leaflets and the mitral annulus. Alteration to any of these can lead to the development of mitral regurgitation (MR). MR is the most prevalent valvular heart disease and the second most frequent condition requiring surgery.<sup>1</sup> It is an insidious disorder that develops gradually over many years and carries an annual mortality rate of at least 5%.<sup>2,3</sup> The mechanisms of MR can be classified in two broad-ranging groups according to the underlying disorder: primary when MR results from an intrinsic alteration of the MV apparatus,<sup>2</sup> and functional or secondary when the MV is structurally normal and MR arises from alterations in left ventricular (LV) geometry.<sup>1</sup>

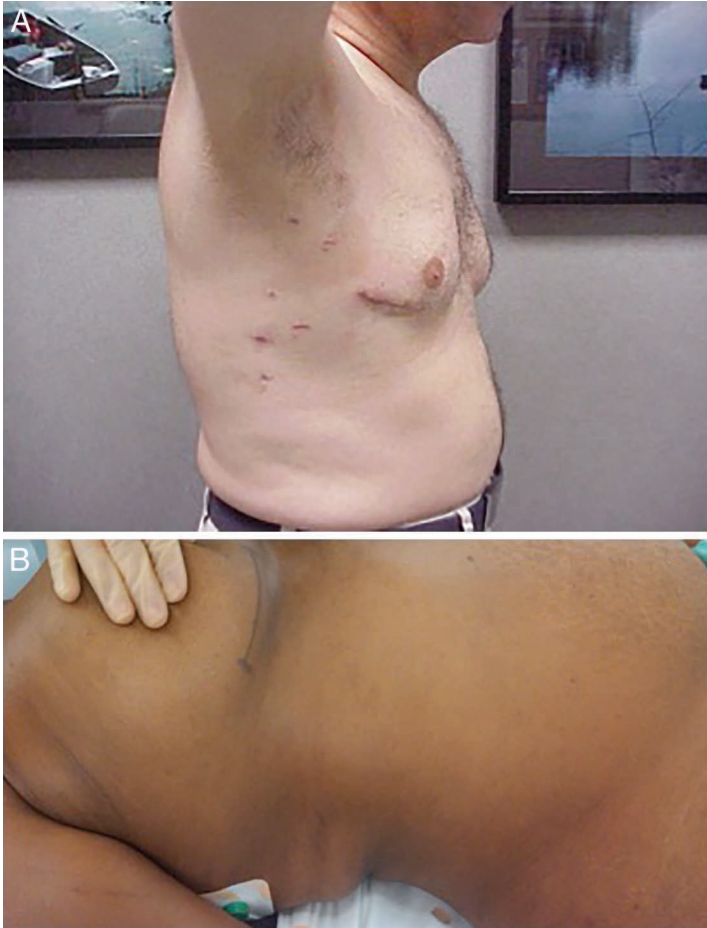Less invasive approaches to MV surgery have been developed since the 1990s with the goal of decreasing the invasiveness and morbidity of mitral valve operations. When compared to traditional sternotomy MV procedures, minimally invasive cardiac surgery (MICS) has demonstrated equally good hard outcomes such as survival, stroke, and renal failure while improving on secondary important outcomes such as hospital length of stay, transfusion requirements, and postoperative atrial fibrillation. Ultimately, the approach with which the MV is repaired is secondary to optimal repair rates and quality and clinical outcomes. Both patients and their referring physicians are attracted to less-invasive options for the surgical treatment of mitral valve disease. Below we outline the most commonly used examples of these procedures.

## Minimally Invasive Mitral Valve Repair or Replacement

Most MV pathology can be treated with minimally invasive, sternal-sparing approaches through the right chest via a mini-antrolateral thoracotomy (Figures 1 A, B). These MICS procedures

are usually performed through the third or fourth intercostal space using a limited 5- to 8-cm incision along the inframammary crease. The patient is commonly positioned supine with a slight bump under the right hemi-thorax to allow complete access to the sternum and both groins. Use of adjunct-enabling technology such as percutaneous retrograde cardioplegia delivery (e.g., EndoPlege®, Edwards Lifesciences Corp., Irvine, CA), pulmonary artery venting (e.g., EndoVent, Edwards Lifesciences Corp.), and rapid-fire suture ligation devices (e.g., Cor-KNOT®, LSI Solutions, Victor, NY) may be preferred by some surgeons for a faster procedure and improved visualization through the limited incision (Figure 2).

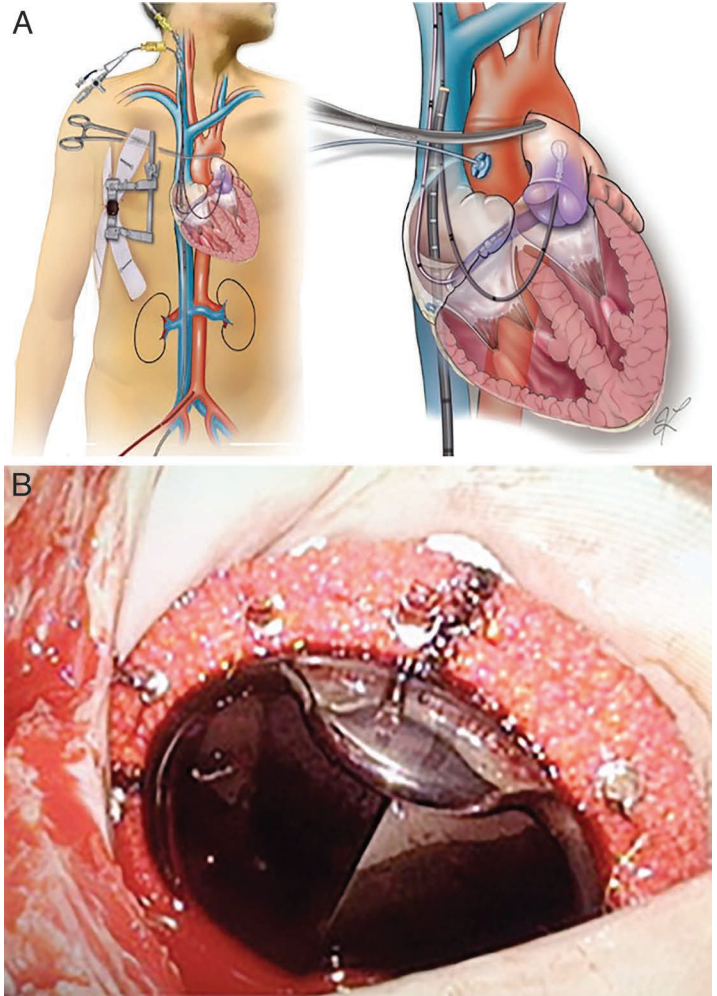
Once the intercostal space is entered, the right lung is deflated (single-lung ventilation) and a soft-tissue retractor is placed. Pericardium is visualized and opened horizontally superior to the phrenic nerve, taking care to avoid injury with traction or cautery. Cardiopulmonary bypass can be instituted via peripheral cannulation of the femoral vein and artery. Optimal venous drainage is essential for small-incision mitral valve surgery, and many surgeons prefer both femoral venous and right internal jugular/svc cannulae. If antegrade arterial blood flow is preferred, then direct aortic or axillary arterial cannulation can be performed. An antegrade cardioplegia catheter is inserted into the ascending aorta, and an aortic clamp is typically performed using a flexible cross-clamp. Care needs to be taken not to injure the pulmonary artery or left atrial appendage when applying the aortic cross-clamp. Similar to open sternotomy, antegrade and retrograde cardioplegia can be administered normally throughout the procedure. Once the heart is arrested, the left atrium (LA) is opened through a traditional approach via Waterston's groove directly anterior to the right-sided pulmonary veins, and retraction anteriorly is performed by the atrial lift retractor to expose the LA



**Figure 1.** (A) Postoperative and (B) intraoperative pictures of minimally invasive mitral valve repair incisions.

cavity and MV. Alternatively, a right atriotomy and transeptal approach can be used. If right atrial entry is required for work on the tricuspid valve or for a transeptal approach to the MV, then separate superior vena cava direct cannulation is performed through the working incision or via jugular vein peripheral cannulation and snaring of the vena cavae. Once MVR/r is completed, the LA is closed and special care is given to complete de-airing of the heart. De-airing of the heart is essential and can be accomplished anteriorly through an aortic root vent or through carbon dioxide insufflation, filling of cardiac chambers, and retrograde cardioplegia. The patient is then weaned from cardiopulmonary bypass and cannulae are removed. In most cases an intercostal space nerve block is performed (Table 1).

While most MVR/r techniques can be performed via MICS approaches as described, selection of patients should be done with care to avoid potential complications. Patients with aortic calcification, RV dysfunction, endocarditis, or severe mitral annular calcification are considered relative contraindications for an MICS MVR/r approach (Table 2). Also, the learning curve for MICS MVR/r procedures has been shown to be quite lengthy and has varied between 75 and 125 procedures per surgeon.<sup>4</sup> While outcomes improve significantly over time, few cardiac surgeons have such large volumes of mitral procedures to overcome this long learning curve. It is important that surgeons embarking on a less-invasive MV surgical program should have substantial experience in MV repair techniques. The primary imperative of an MV operation for degenerative disease is a safe, effective, and



**Figure 2.** (A) Intraoperative setup and peripheral cannulation for minimally invasive mitral valve surgery, courtesy of Edwards Lifesciences Corp. (B) Mitral valve replacement with Kor-Knot suture ligature device.

lasting, durable MV repair, with location and size of incision a secondary concern.

In recent years, percutaneous treatment of MR has aroused great interest, and several devices have been developed for percutaneous MVR/r. These interventional methods are modeled in most cases from established surgical heart valve procedures. These in turn have started to evolve to less-invasive approaches that can be used in patients at high risk for surgery due to coexisting comorbidities—addressing a large unmet clinical need.<sup>5</sup>

### Transcatheter Mitral Valve Repair

Mitral valve repair surgery, when feasible, is the preferred approach over valve replacement since it is associated with lower rates of short- and long-term mortality and morbidity, better preservation of ventricular function, and a greater likelihood of avoiding anticoagulation therapy and/or reoperation for structural valve dysfunction.<sup>6</sup> At least 50% of patients with severe MR are not candidates for surgery due to their age or other comorbidities.<sup>7</sup>

Percutaneous MV repair technology is generally based on the same principles as MV surgery: neochordae placement, leaflet plication, annuloplasty, papillary modification, and LV remodeling. Most percutaneous annuloplasty technology targeting coronary sinus implantation thus far has failed to progress in development due to technical and safety shortcomings as the coronary sinus is

MICS Mitral Valve Surgery Steps
1. Supine with bump under right hemithorax
2. Expose groins and sternum
3. Defibrillation pads
4. Jugular-coronary sinus retrograde catheter (anesthesia)
5. 6- to 8-cm anterolateral thoracotomy (3rd or 4th ICS)
6. CPB: ascending aorta & femoral vein (percutaneous)
7. Transesophageal electrocardiogram guidance
8. Transthoracic Chitwood clamp (via transverse sinus)
9. Mobilize SVC and develop oblique sinus
10. Standard MV repair approach
MICS: minimally invasive coronary surgery; ICS: intercostal space; CPB: cardiopulmonary bypass; TEE: transesophageal echocardiography; SVC: superior vena cava; MV: mitral valve

**Table 1.** Ten steps to minimally invasive mitral valve surgery.

not colocalized with the mitral annulus (i.e., it is typically atrially displaced relative to the annulus), and the circumflex coronary artery was at risk for compression/distortion by these devices (e.g., Edwards MONARC™ System, Viacor PTMA Implant System). The one system that has gained approval in Europe with the CE mark, the CARILLON® Mitral Contour System, has had poor adoption largely due to lack of clinical efficacy.

The MitraClip® (Abbott Laboratories, Abbott Park, IL) is the only percutaneous TMVR/r approved device that allows a transvenous percutaneous transeptal approach to create an edge-to-edge repair for MR.<sup>8,9</sup> Based on the surgical Alfieri repair, the MitraClip received CE mark approval in 2008 and FDA approval in 2013 for patients with severe degenerative MR who are at prohibitive surgical risk. Catheter-based mitral repair with this device was first performed in patients in 2003. To date, the MitraClip system has been implanted in more than 15,000 patients worldwide. The MitraClip is a mechanical clip composed of a cobalt-chromium metal alloy covered by polypropylene fabric; once inserted, it permanently opposes the middle of the anterior and posterior mitral leaflets. A double orifice is created, and the subvalvular apparatus is spared. The procedure is performed under general anesthesia with fluoroscopic and transesophageal echocardiographic guidance. The MitraClip and delivery system are passed through a steerable guide 24F catheter that tapers to a 22F diameter as it enters the LA via a transeptal puncture. The MitraClip is navigated from the LA into the LV above the origin of the MR jet. Once across the orifice, the open clip is slowly pulled back, allowing the leaflets to fall into the arms, which are then closed to grasp the leaflet edges. Successful grasping results in immediate reduction in the degree of MR. An assessment is made to ensure stability of the device and leaflets, and then the clip is closed. The operator may release and readjust the position of the clip to optimize MR reduction (Figure 3). In approximately 40% of cases, a second clip may be required to achieve sufficient reduction in MR if the degree of MR was insufficient from the first attempt. Three clips are used in approximately 1% of cases, and the use of as many as 4 clips has been described.<sup>10-12</sup>

While not percutaneous at this stage, there are two leaflet repair technologies currently in early phase clinical trials. The Neo Chord device (NeoChord Inc., Eden Prairie, MN) and the Harpoon Medical device (Harpoon Medical, Inc., Baltimore, MD)

Mitral annular calcification
Endocarditis
Ascending aortic calcification
Adhesions (redo/radiation)
Concomitant CABG
LV dysfunction
Aortic insufficiency
Peripheral vascular disease
Chest wall deformity

**Table 2.** Relative contraindications to minimally invasive mitral valve surgery.

both deliver expanded polytetrafluoroethylene artificial chords via a limited anterolateral minithoracotomy and transapical LV puncture under echo guidance on a beating heart. Both devices allow for adjustment of the prolapsed leaflet tethering chords and anchoring to the LV epicardium under transesophageal echocardiographic (TEE) guidance to optimize the coaptation surface. The NeoChord DS 1000 system achieved successful placement of at least one leaflet chord and reduction of MR to  $\leq 2+$  in 86.7% of patients in their proof-of-concept TACT study (Figure 4).

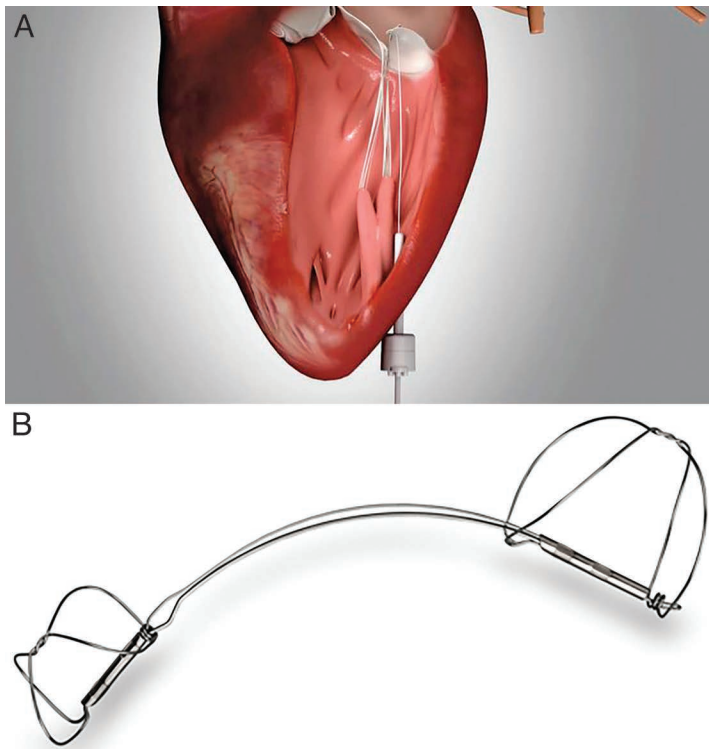
The Mitralign® device (Mitralign, Inc., Tewksbury, MA) allows for placement of MV annular pledgeted sutures to achieve annular size reduction. Under TEE guidance, a catheter is delivered retrogradely from the aorta through the AV, which then allows two wires to be introduced from the LV into the LA at two adjacent points. These wires are used to place pledgets on both the LA and LV sides and are cinched using a steel lock, thus reducing annular circumference. Similar to other devices, the Mitralign has shown modest improvements in clinical MR grade and clinical symptom improvement (Figure 5).

Other devices have also been developed to perform a MV annuloplasty. One of these is the Valtech Cardioband device (Valtech Cardio, Or Yehuda, Israel) that delivers a series of 15



**Figure 3.** Abbott MitraClip device for percutaneous mitral valve repair. Courtesy of Abbott Laboratories.





**Figure 4.** (A) Transapical mitral valve neochordal insertion with Harpoon device, courtesy of Harpoon Medical Inc. (B) Carillion Mitral Contour System for percutaneous coronary sinus mitral annuloplasty repair, courtesy of Cardiac Dimensions, Inc.

to 16 screws into the atrial aspect of the MV annulus through a transeptal catheter, then cinches the MV annulus under TEE observation to reduce the septal-lateral dimension of the MV annulus. Another device is the GDS Accucinch® System (Guided

Delivery Systems, Inc., Santa Clara, CA), which delivers an annuloplasty band through a retrograde aortic approach into the LV side of the MV annulus.

Regardless of the approach used by these novel catheter-based procedures, it is becoming increasingly clear that catheter-based approaches should incorporate MV surgical principles, including preserving and restoring full leaflet motion, creating a large surface of coaptation, and stabilizing the MV annulus.

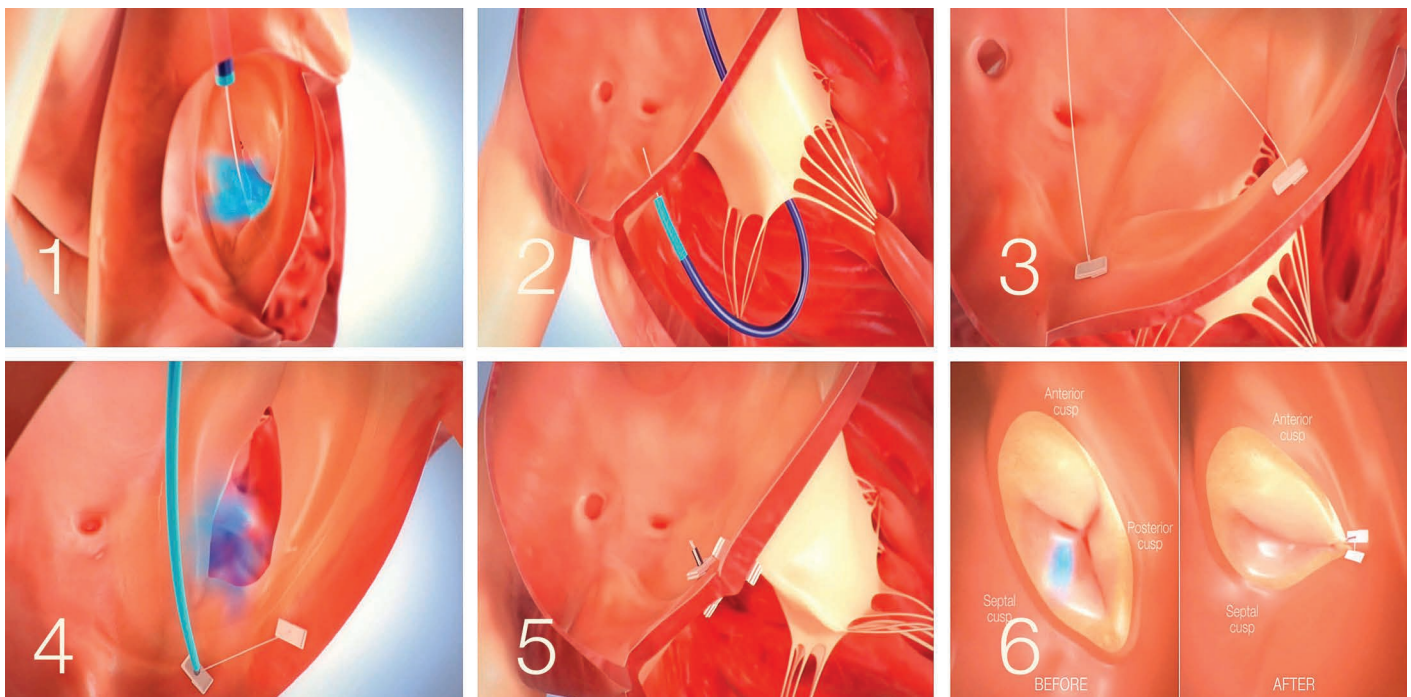
### Transcatheter Mitral Valve Replacement

While a strategy of MV repair is usually preferred in cases of MR, the challenges in developing a viable MV repair technology have led researchers to focus on MV replacement as a potentially simpler approach. Many centers now use the Edwards Sapien transcatheter heart valve (Edwards Lifesciences Corp.) in an off-label application of transcatheter mitral valve replacement (TMVr) for patients with degenerated MV surgical prostheses or within annuloplasty rings. These replacement strategies can be performed successfully via transapical or transeptal approaches.

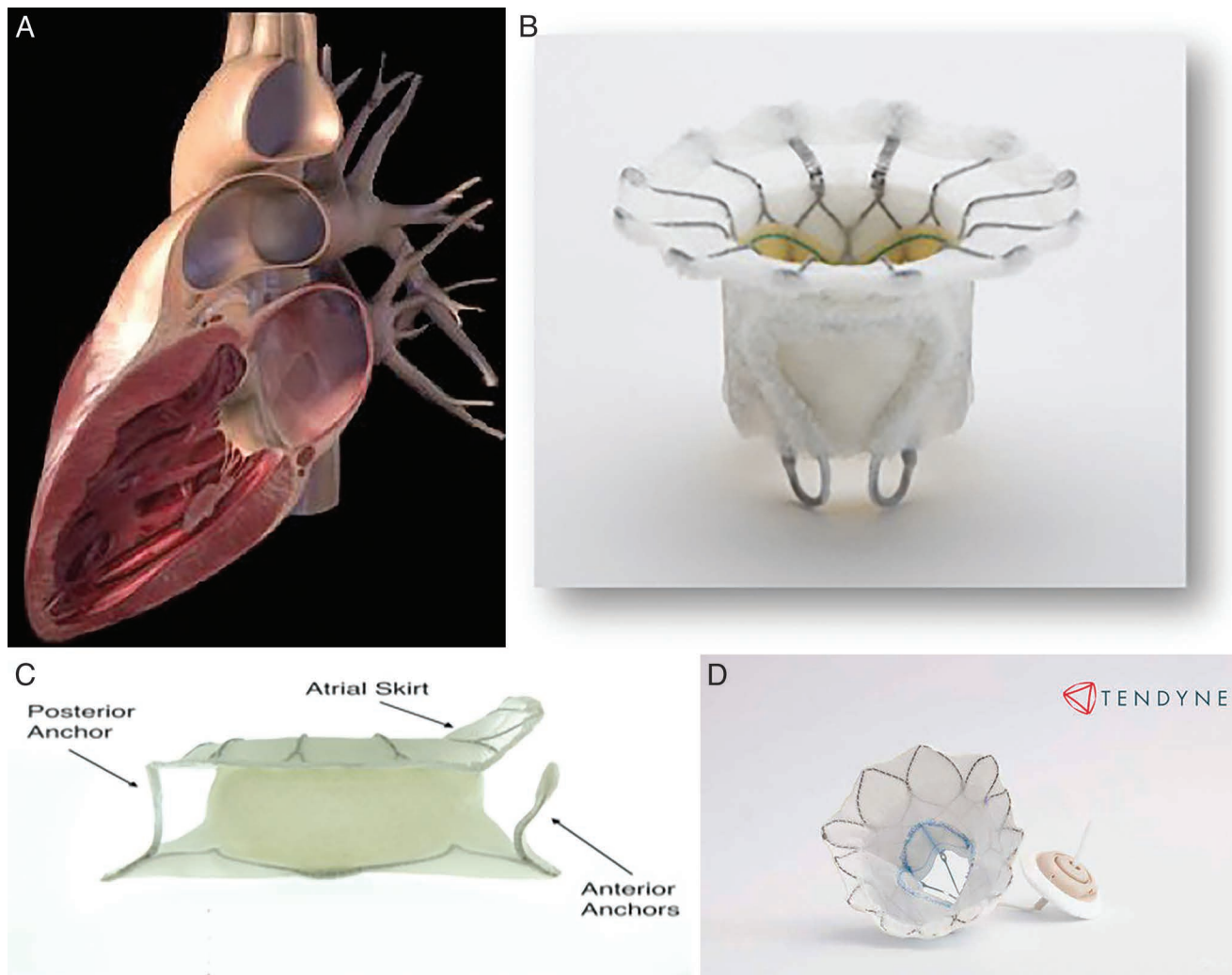
Transcatheter MV replacement could potentially become the technique of choice in patients with severe MR and at high risk for surgery. As we learned from the TAVR experience, heart teams are increasingly choosing catheter-based options for valvular disease as technological refinements and studies show validity of expanding indications. However, the complexity of the MV, the varied etiology of pathology, and incomplete knowledge of the MR mechanism have delayed development of TMVr/r parallel to percutaneous treatment of aortic stenosis.

Several factors have slowed the development of a percutaneous MV prosthesis:

- The asymmetry of the mitral annulus
- Absence of a single valvular plane
- The constant movement of the mitral annulus and the basal part of the LV, which makes stable anchoring of the prosthesis challenging



**Figure 5.** Mitralign percutaneous annuloplasty system, courtesy of Mitralign Inc.



**Figure 6.** Transcatheter mitral valve replacement investigational devices. (A) CardiaQ, courtesy of CardiaQ Valve Technologies, Inc. (B) Fortis, courtesy of Edwards Lifesciences Corp. (C) Tiara, courtesy of Neovasc Inc. (D) Tendyne, courtesy of Abbott Laboratories.

- The proximity of the MV to the aortic valve and LV outflow tract
- The complexity and variability of the subvalvular apparatus (chordae tendinae and papillary muscles)
- The heterogeneity of pathology and physiology of patients presenting with mitral regurgitation (organic vs functional vs mixed disease)
- Calcification of the MV annulus
- The anatomic variability of the mitral annulus

There are currently many start-up companies intent on developing the optimal TMVr technology. Most have focused on the transapical delivery approach to further simplify the delivery method. Initial attempts at TMVr include the Endovalve-Herrmann prosthesis (Endovalve, Inc., Princeton, NJ), which is implanted via a minithoracotomy approach with no need for extracorporeal circulation. Using specially designed teeth, the valve is anchored and can be repositioned prior to release. Another is the bovine pericardium Lutter valve (University of Kiel School of Medicine, Kiel, Germany) that is mounted on a self-expandable nitinol stent.

The FORTIS transcatheter mitral valve (Edwards Lifesciences Corp.) is a self-expanding device implanted via a transapical

approach. It is made of a cloth-covered, self-expanding nitinol stent with three bovine pericardial leaflets. At present only the 29-mm valve is available for clinical use. The FORTIS valve consists of three main components, including a central valve body, the paddles, and an atrial flange. The central valve body is a cylindrical central portion of 29-mm diameter that harbors the three leaflets. The leaflets are similar to those used in other surgical and transcatheter valves manufactured by Edwards Lifesciences and are sutured to the stent. This system uses a dedicated FORTIS mitral transcatheter sheathless 42F delivery system for device implantation. Following several first-in-man implants, Edwards recently announced that they would halt activity on this device (Figure 6 A-D).

The porcine pericardium CardiaQ valve (CardiaQ Valve Technologies, Inc., Winchester, MA) is also mounted on a self-expandable nitinol stent designed for transseptal implantation. This is the first percutaneous valve implanted in the mitral position in a native valve.<sup>13</sup> The procedure was performed in Denmark on an 86-year-old man with severe MR. Residual MR was grade 1+ after the procedure, with an initially favorable clinical course; however, the patient died of multiorgan failure at postoperative day 3. The autopsy found no structural failure of the valve. Edwards Lifesciences Corp. recently acquired CardiaQ



with plans to either replace or supplement their FORTIS valve technology.

The Tendyne Bioprosthetic Mitral Valve System, recently acquired by Abbott Medical Inc. (Abbott Laboratories), has been successfully implanted in patients using an off-pump transapical approach. The Tendyne device is a fully retrievable and repositionable, apically tethered tri-leaflet porcine pericardial valve sewn onto a nitinol frame. It was specifically designed to address the complex mitral anatomy of functional, degenerative, and mixed etiology mitral regurgitation.

The bovine pericardium Tiara valve (Neovasc, Inc., Richmond, British Columbia) is mounted on a self-expandable stent with a D-shaped atrial portion that adjusts better to the anatomy of the mitral annulus and avoids LV outflow tract obstruction. The ventricular portion has three anchoring structures with an outer coating to avoid paravalvular leaks. It is implanted via a transapical approach using a 30F catheter.<sup>14</sup>

Recently, Medtronic acquired Twelve Inc, a privately held company with proprietary TMVr technology to further solidify their place in this expanding MV marketplace.

## Conclusion

The majority of MV operations currently performed in North America are for patients with degenerative MV disease. Repair is clearly superior to replacement for degenerative MV disease, and successful beating-heart/small incision and transcatheter technologies will be based on time-tested surgical approaches and will afford patients less-invasive durable MV repair options. These image-guided technologies may improve the quality and durability of repairs. In contrast, functional MR is prevalent but not commonly treated with surgery. It remains unclear if treatment in the functional MR population is of significant clinical benefit, given that the underlying problem is a ventricular rather than valvular one. The CoAPT trial, currently enrolling patients with functional ischemic MR into either therapy with a MitraClip or best medical therapy, will provide important information as to the value of treating functional MR, albeit with a device that is not as effective as surgery at fixing functional MR. If transapical or transcatheter MV replacement can be achieved in a safe and durable fashion, then we will be poised to perform a clinical trial assessing the clinical benefits of this approach. It would be a mistake to use these replacement devices in patients with degenerative disease since we know the benefits of repair compared to replacement are very substantial in this population.

Transcatheter devices are primarily based upon well-known surgical techniques that have subsequently progressed to less-invasive approaches. It is important to emphasize that, for the time being, novel percutaneous devices used in the treatment of MR are not meant to replace surgical techniques in low-risk patient groups who are good candidates for surgery. Among all catheter-based mitral therapies, the leaflet repair MitraClip system has the largest clinical experience worldwide, with an established and reproducible safety profile and reasonably effective reduction of MR in high-risk surgical patients. While TMVR/r is gaining significant traction as the next major development in valve therapy (following TAVR), there are several challenges that will need to be addressed. These include technology design, delivery methods that do not affect surrounding anatomy, and identifying the most appropriate patient population to benefit from this technology (i.e., those with inoperable organic MR vs functional MR). Improved

interventional imaging, such as 3-dimensional TEE, will surely play a pivotal role in advancing this field. Importantly, TMVR/r has the potential to overtake TAVR as the most commonly performed catheter-based structural heart intervention due to the prevalence of the population at risk.

**Conflict of Interest Disclosure:** Dr. Ramlawi is a consultant for Medtronic, Inc., Sorin Group, and AtriCure, Inc., has equity in Replicore Inc., and receives research funding from Baxter BioSciences and Medtronic. Dr. Gammie is co-founder of Harpoon Medical, Inc.

**Keywords:** mitral valve, mitral regurgitation, TMVR, transcatheter mitral valve repair

## References

1. Enriquez-Sarano M, Akins CW, Vahanian A. Mitral regurgitation. *Lancet*. 2009 Apr 18;373(9672):1382-94.
2. Castillo JG, Solís J, González-Pinto A, Adams DH. Ecocardiografía quirúrgica de la válvula mitral. *Rev Esp Cardiol*. 2011 Dec;64(12):1169-81.
3. Bonow RO, Carabello BA, Chatterjee K, et al; 2006 Writing Committee Members; American College of Cardiology/American Heart Association Task Force. 2006 Focused update incorporated into the ACC/AHA 2006 guidelines for the management of patients with valvular heart disease: a report of the American College of Cardiology/American Heart Association Task Force on Practice Guidelines (Writing Committee to Revise the 1998 Guidelines for the Management of Patients With Valvular Heart Disease): endorsed by the Society of Cardiovascular Anesthesiologists, Society for Cardiovascular Angiography and Interventions, and Society of Thoracic Surgeons. *Circulation*. 2008 Oct 7;118(15):e523-661.
4. Holzhey DM, Seeburger J, Misfield M, Borger MA, Mohr FW. Learning minimally invasive mitral valve surgery: a cumulative sum sequential probability analysis of 3895 operations from a single high-volume center. *Circulation*. 2013 Jul 30;128(5):483-91.
5. Feldman T, Leon MB. Prospects for percutaneous valve therapies. *Circulation*. 2007 Dec 11;116(24):2866-77.
6. Vahanian A, Alfieri O, Andreotti F, et al.; Joint Task Force on the Management of Valvular Heart Disease of the European Society of Cardiology (ESC); European Association for Cardio-Thoracic Surgery (EACTS). Guidelines on the management of valvular heart disease (version 2012). *Eur Heart J*. 2012 Oct;33(19):2451-96.
7. Mirabel M, lung B, Baron G, et al. What are the characteristics of patients with severe, symptomatic, mitral regurgitation who are denied surgery? *Eur Heart J*. 2007 Jun;28(11):1358-65.
8. Maisano F, Viganò G, Blasio A, Colombo A, Calabrese C, Alfieri O. Surgical isolated edge-to-edge mitral valve repair without annuloplasty: clinical proof of the principle for an endovascular approach. *EuroIntervention*. 2006 Aug;2(2):181-6.
9. St Goar FG, Fann JI, Komtebedde J, et al. Endovascular edge-to-edge mitral valve repair: short-term results in a porcine model. *Circulation*. 2003 Oct 21;108(16):1990-3.
10. Maisano F, Schreuder JJ, Oppizzi M, Fiorani B, Fino C, Alfieri O. The double-orifice technique as a standardized approach to treat mitral regurgitation due to severe myxomatous disease: surgical technique. *Eur J Cardiothorac Surg*. 2000 Mar;17(3):201-5.
11. Chen X, Turley RS, Andersen ND, Desai BS, Glower DD. Minimally invasive edge-to-edge mitral repair with or without artificial chordae. *Ann Thorac Surg*. 2013 Apr;95(4):1347-53.

12. Kische S, Nienaber C, Ince H. Use of four MitraClip devices in a patient with ischemic cardiomyopathy and mitral regurgitation: “zipping by clipping”. *Catheter Cardiovasc Interv.* 2012 Nov 15;80(6):1007-13.
13. Sondergaard L. CardiAQ program update: Featuring the world's first successful transcatheter mitral valve implant. Abstract presented at: Transcatheter Cardiovascular Therapeutics 24th Annual Scientific Symposium. 2012 Oct. 22-26; Miami, FL.
14. Banai S, Jolicoeur EM, Schwartz M, et al. Tiara: a novel catheter-based mitral valve bioprosthesis: initial experiments and short-term pre-clinical results. *J Am Coll Cardiol.* 2012 Oct 9;60(15):1430-1.